

Herpes Zoster and Postherpetic Neuralgia: Diagnosis and Therapeutic Considerations

Mario Roxas, ND

Abstract

Herpes zoster (HZ), also known as shingles, is a painful vesicular rash resulting from reactivation of the virus that also causes chickenpox – *Varicella zoster virus (VZV)*. Typically, the rash runs its course in a matter of 4-5 weeks. The pain, however, may persist months, even years, after the skin heals. This phenomenon is known as postherpetic neuralgia (PHN). Often described as an intense burning, itching sensation, this pain can be significant to the point of being debilitating, and as such can greatly affect quality of life. Although shingles is generally regarded as a self-limited condition, the fact it can take several weeks to resolve and has the potential for development of complications such as PHN presents a challenge to clinicians. Many treatment options are available, each offering variable levels of efficacy. Conventional therapies include prescription antivirals, corticosteroids, and analgesics, both oral and topical. Other considerations include use of over-the-counter anti-inflammatory agents, physiotherapy, and nerve block injections. This article reviews herpes zoster and postherpetic neuralgia, and presents the most effective conventional treatment options currently available, as well as select botanical, nutritional, and other considerations that may be beneficial in the management of this condition. (*Altern Med Rev* 2006;11(2):102-113)

Introduction

Herpes zoster (HZ) is the reactivated form of the *Varicella zoster virus (VZV)*, the same virus responsible for chickenpox. HZ is more commonly known as shingles, from the Latin *cingulum*, for “girdle.” This is because a common presentation of HZ involves a unilateral rash that can wrap around the

waist or torso like a girdle. Similarly, the name zoster is derived from classical Greek, referring to a belt-like binding (known as a zoster) used by warriors to secure armor.

Annually, over 500,000 people in the United States experience a shingles outbreak.¹ Over 90 percent of the adult population in the United States has serological evidence of a prior VZV infection and thus are at risk for developing shingles.² There is no way to predict who will develop HZ, when the latent virus may reactivate, or what may trigger its reactivation. However, the elderly and those with compromised immunity – such as those who have undergone organ transplantation or recent chemotherapy for cancer, or individuals with HIV/AIDS – are at greater risk for developing HZ. Between 10-20 percent of normal (immunocompetent) adults will get shingles during their lifetime.^{1,3,4} This figure increases dramatically to 50 percent for those over age 85 years.⁵

Etiology and Pathology

VZV is one of eight known herpes viruses that infect humans (Table 1). Its structure is characterized by an icosahedral nucleocapsid surrounded by a lipid envelope. Double-stranded DNA is located at its center. The virus is approximately 150-200 nm in diameter and has a molecular weight of approximately 80 million.⁶

Primary infection is clinically identified as Varicella or chickenpox. VZV is ubiquitous and highly contagious, with initial exposure typically occurring during childhood. The virus enters the host via the respiratory system, replicates at an undefined site (presumably the nasopharynx), infiltrates the

Mario Roxas, ND – technical advisor, Thorne Research; associate editor, *Alternative Medicine Review*; private practice.
Email: m.roxas@comcast.net

Table 1. Human Herpes Viruses

Human Herpes Virus (HHV)	Common Associated Disease
<i>Herpes simplex</i> , type 1 (HSV-1)	Oral herpes lesions
<i>Herpes simplex</i> , type 2 (HSV-2)	Genital herpes lesions
<i>Varicella zoster virus</i> (VZV)	Chickenpox, shingles
Epstein-Barr virus (EBV)	Infectious mononucleosis
Cytomegalovirus (CMV)	CMV mononucleosis
Human herpes virus 6 (HHV-6)	Roseola, mononucleosis syndromes
Human herpes virus 7 (HHV-7)	Currently, no human disease definitely linked
Human herpes virus 8 (HHV-8)	Suspected association with Kaposi's sarcoma

reticuloendothelial system, and eventually makes its way into the bloodstream. Evidence of viremia is manifested by the scattered nature of the telltale skin lesions on the body.

The usual incubation period for Varicella is 14-16 days, with communicability ranging from 10-21 days after initial exposure. An individual can no longer transmit VZV once the final skin lesions have crusted. Indirect transmission (via an immune third person) is not thought to occur.⁷

Once the initial outbreak has subsided, VZV then retreats into the dorsal root ganglia where it can lie dormant for years until some excitatory factor triggers reactivation. The associated outbreak is then clinically identified as HZ or shingles. Microscopic examination of select dorsal root ganglia tissue during active HZ shows presence of hemorrhage, edema, and lymphocytic infiltration.⁶ Figure 1 illustrates the typical progression of VZV from Varicella to zoster.

Lowered cellular immunity places an individual at risk for HZ, hence the susceptibility of immunocompromised individuals and the elderly. It has been proposed that one reason VZV may not recur as frequently as other herpes viruses, such as *Herpes simplex*, type 1 (HSV-1) or *Herpes simplex*, type 2 (HSV-2), is that genes involved in reactivation of HSV are missing in VZV.⁸

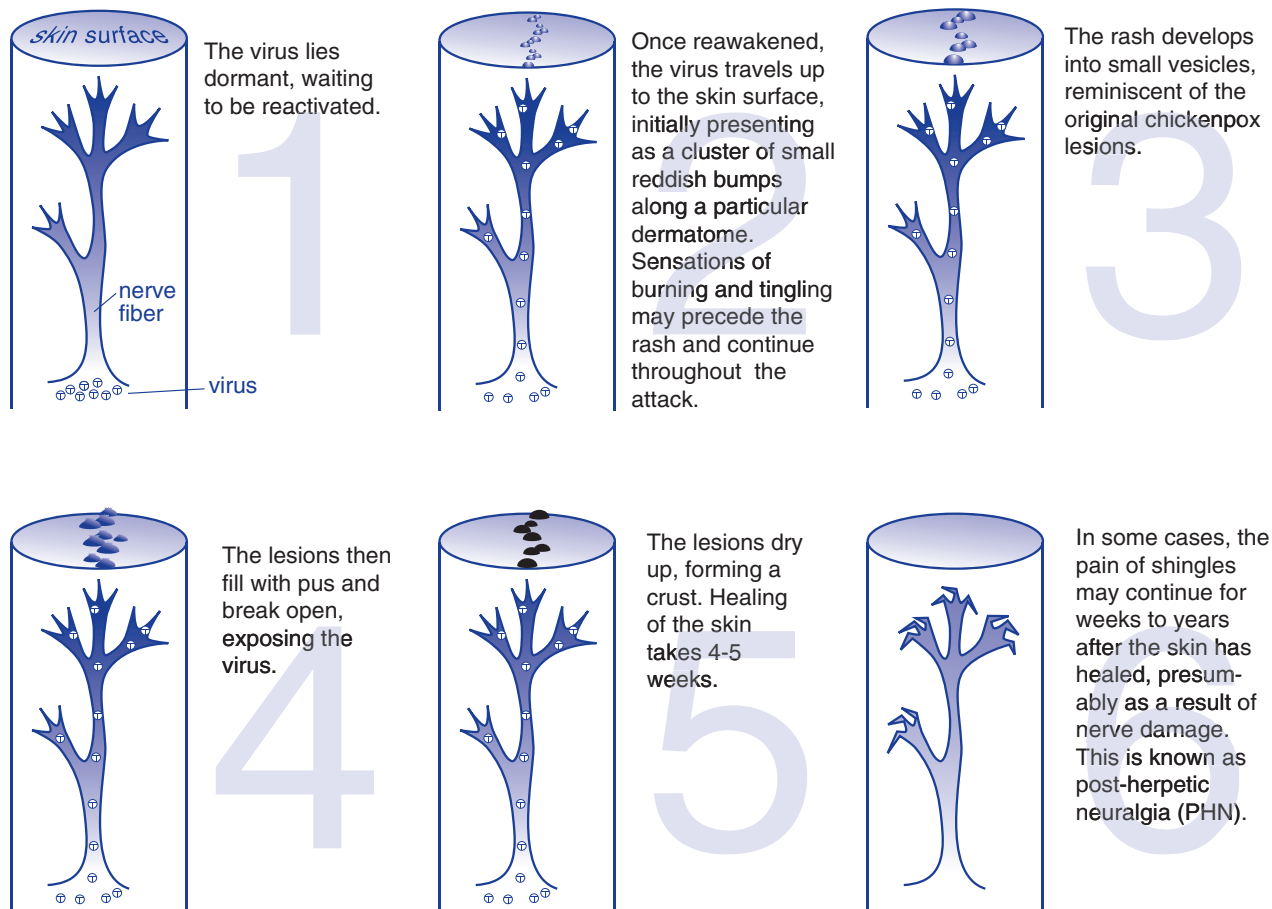
Signs and Symptoms

The classic presentation of HZ starts with a prodrome of mild-to-moderate burning or tingling (or in some cases numbness) in or under the skin of a given dermatome, often accompanied by fever, chills, headache, stomach upset, and general malaise. Within 48-72 hours from the prodrome, an erythematous, maculopapular rash forms unilaterally along the dermatome and rapidly develops into vesicular lesions reminiscent of the original chickenpox outbreak. The pain associated with shingles varies in intensity from mild to severe,⁵ such that even the slightest touch or breeze can elicit excruciating spasms. The lesions usually begin to dry and scab 3-5 days after appearing. Total duration of the disease is generally between 7-10 days; however, it may take several weeks for the skin to return to normal.

Complications

The most common complication associated with HZ is the development of postherpetic neuralgia (PHN), a condition where pain accompanying the rash persists long after the lesions have healed. This pain has been characterized as an unrelenting sharp, burning, stabbing pain, capable of making unbearable the most menial activities of everyday life, such

Figure 1. Progression of Varicella



Adapted from: www.fda.gov/fdac/features/2001/301_pox.html [Accessed May 1, 2006]

as bathing or dressing. PHN is of particular concern with increasing age because it is estimated that half the individuals over age 50 who develop shingles also develop PHN.⁹ Other potential complications of HZ include encephalitis, myelitis, peripheral nerve palsies, and forms of contralateral hemiparesis.²

Although unilateral presentation is most common, HZ may become generalized, which is often indicative of compromised immunity or underlying malignancy. Prior to antiviral drugs, cutaneous dissemination of HZ was reported in 6-26 percent of immunocompromised patients. Of these patients, up to 50 percent manifested some evidence of visceral involvement, resulting in complications such as pneumonitis, encephalitis, or hepatitis.¹⁰ Generalized

cutaneous HZ may also arise in immunocompetent individuals, albeit to a far lesser degree in both frequency and severity.¹¹ Thus, it is prudent to rule out the possibility of underlying malignancy or immune dysfunction, should this presentation arise.

The dermatomes from T3 to L3 are most commonly involved in HZ (Figure 2). However, in some cases, the virus may afflict the cranial nerves, which can lead to complications.

Involvement of the trigeminal nerve (cranial nerve V) can result in lesions appearing on the face, in the mouth, in the eye, or on the tongue. Zoster ophthalmicus is a form of HZ involving the ophthalmic ganglion of the trigeminal nerve, resulting in painful eye inflammation that can impair vision and in some cases cause temporary blindness. HZ ophthalmicus

accounts for approximately 10-25 percent of HZ cases.¹² If not treated promptly, permanent damage can occur, including chronic ocular inflammation, debilitating pain, and vision loss.

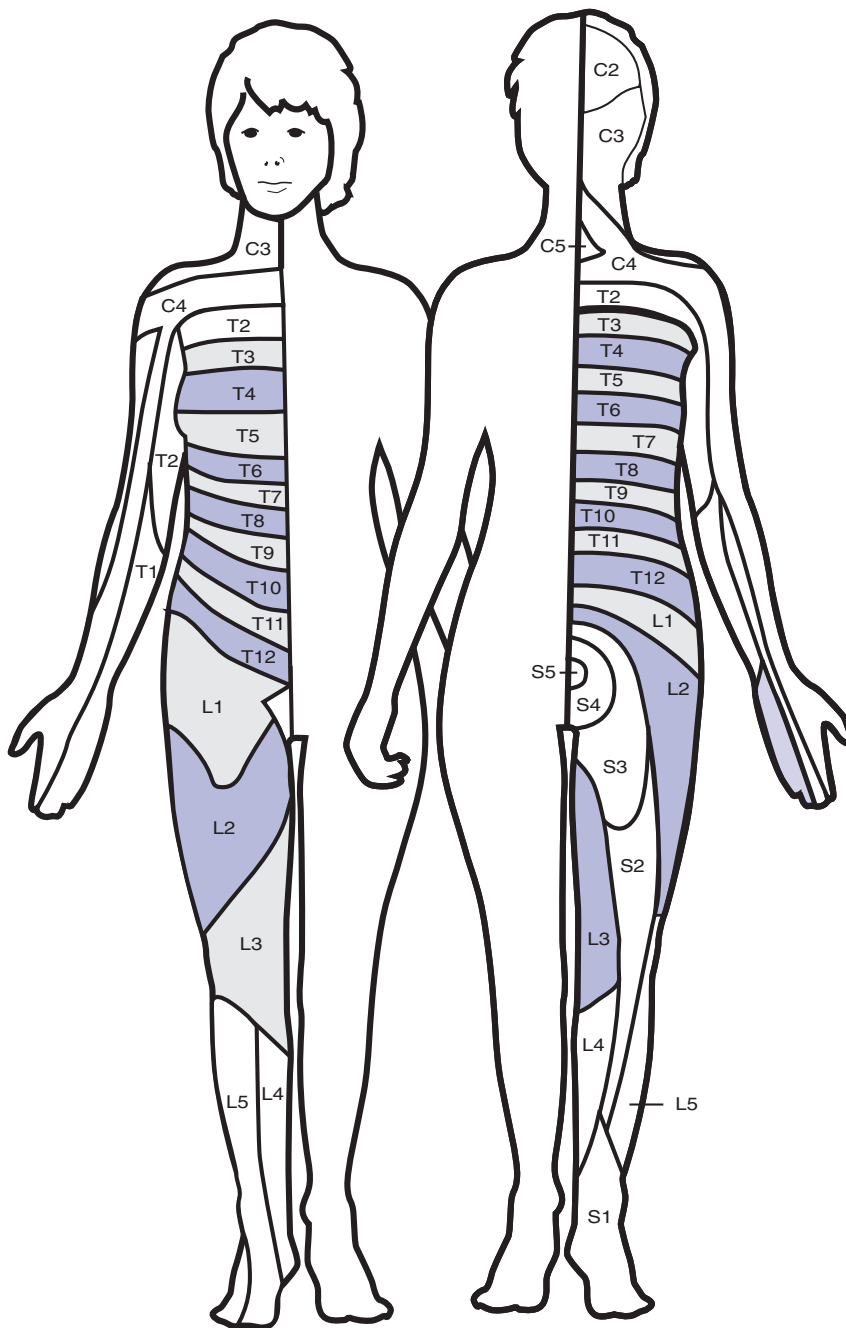
Ramsay-Hunt Syndrome is a fairly rare manifestation of HZ involving the geniculate ganglion of the facial nerve (cranial nerve VII). The auditory nerve (cranial nerve VIII) can also be affected.¹³ The pain and lesions appear in the external auditory canal and are often accompanied by vertigo, tinnitus, facial paresis, and ipsilateral hearing loss.¹⁴ In addition, loss of taste in the anterior two-thirds of the tongue can also occur.⁶ Although considered a self-limiting disease, permanent sequelae can result as complete recovery is estimated to be less than 50 percent. The most common morbidity results in facial weakness on the affected side.¹⁴

Diagnosis

Initial diagnosis poses a challenge during the prodromal stage of the disease, which typically lasts 1-2 days but can persist up to three weeks before the appearance of skin lesions.¹⁵ Furthermore, some individuals may only present with prodromal symptoms, never developing the tell-tale rash. This phenomenon is known as “zoster sine herpette.”

Pain can be misdiagnosed as appendicitis, myocardial infarct, renal colic, cholelithiasis, or colitis, depending on its intensity and the location of the affected nerve.¹⁶ Common differential diagnoses at this stage include pleurisy, cardiac disease, herniated nucleus pulposus, trigeminal neuralgia, and Bell's palsy.^{15,16}

Figure 2. Dermatomes Involved in Herpes Zoster



Although shingles can manifest in any number or variety of dermatomes, T3 to L3 are most commonly affected.

An appropriate diagnosis of HZ is aided by the appearance of a vesicular rash with characteristic distribution. When the presentation of skin lesions is not as clear, as may be the case with immunocompromised patients, laboratory confirmation is recommended. The polymerase chain reaction (PCR) technique is the most sensitive and specific diagnostic test, as it can detect VZV DNA in fluid from the vesicle. Availability of the PCR technique, however, may pose a challenge.¹⁷ Viral culture is possible but typically has low sensitivity. VZV is labile, resulting in difficult recovery of an adequate sample from vesicular fluid. Use of direct immunofluorescence assay is a good alternative to PCR. It is preferred over viral culture, as it is more sensitive, of lower cost, and offers a more rapid turnaround time.²

Conventional Treatment Options

The objective of conventional therapy in the treatment of HZ is to accelerate healing of the lesions, reduce the accompanying pain, and prevent complications. Medications typically prescribed include antiviral agents, corticosteroids, analgesics, non-steroidal anti-inflammatory drugs (NSAIDs), and tricyclic antidepressants.

Antiviral Agents

Currently, treatment of HZ with antiviral medication appears to be the method of choice, particularly when treating elderly and immunocompromised patients. Although multiple clinical investigations have demonstrated efficacy in reducing both duration of the rash and severity of the associated pain,^{9,18-21} benefit has only been demonstrated in patients who receive treatment within 72 hours after onset of the rash. Efficacy for prevention of PHN is not as definitive, with studies observing only moderate benefit in reducing its development.²²

The three most commonly used antiviral agents, acyclovir (Zovirax[®]), valacyclovir (Valtrex[®]), and famciclovir (Famvir[®]), demonstrate similar rates of success. These medications are generally well-tolerated, with the most common side effects being abdominal pain, nausea, vomiting, dizziness, and headache.

Corticosteroids

Oral corticosteroids have commonly been used for pain management in HZ, although clinical trials have yielded inconsistent results for reducing development of PHN. One study using a combination of prednisone and acyclovir demonstrated a significant reduction in pain associated with HZ.²³ However, two double-blinded, randomized, controlled trials concluded that administration of corticosteroids for 21 days did not prevent development of PHN.^{23,24}

Analgesics and NSAIDs

The pain associated with HZ covers a broad spectrum of intensity. Generally, individuals with mild-to-moderate pain find sufficient relief via over-the-counter topical or oral analgesics and anti-inflammatory agents, such as aspirin, acetaminophen, or ibuprofen. Several studies have observed that topical aspirin preparations can provide effective temporary relief in cases of acute herpetic neuralgia and PHN.²⁵⁻²⁷ In a randomized trial comparing the efficacy of a topical aspirin-moisturizer (75 mg aspirin/mL of moisturizer three times daily) to oral aspirin (375-750 mg three times daily) on 15 patients for 21 days, the topical preparation provided quicker pain relief (mean time of 44 minutes versus 110 minutes) and longer duration of relief (mean time of 5.4 hours versus 3.5 hours) than oral aspirin.²⁶ One double-blind, comparative clinical trial on 40 patients found topical aspirin was as effective as topical lidocaine in the treatment of PHN.²⁷

In patients with severe pain, use of narcotics may be indicated. A typical recommendation is 30-60 mg of codeine every six hours when necessary.²⁸ In the management of PHN, studies indicate significant pain relief from opioids, such as oxycodone and morphine, compared to placebo.^{29,30} Side effects include nausea, constipation, sedation, and decreased appetite.

Use of nerve block injections is another option in the conventional medical model. Local anesthetic may be injected around the affected nerves, providing pain relief typically lasting 12-24 hours.³¹ Location of nerve block is dependent on the involved dermatome. If the head, neck, or arms are affected, a stellate ganglion block is performed, with injections placed at the base of the neck just above the

collarbone. Dermatomal patterns involving the chest, trunk, or lower extremities are addressed via epidural block. Long-term relief can be accomplished by repeating the procedure 2-3 times within a two-week period, provided it is administered at an early stage of the disease. Even with this in mind, however, the effectiveness of nerve block injections for reducing or preventing PHN is questionable.³²

Tricyclic Antidepressants

Low-dose tricyclic antidepressants (TCAs) have been used for PHN. Although TCAs lessen pain by inhibiting reuptake of serotonin and norepinephrine,¹⁵ they require at least three months for positive effects. In a randomized trial of patients older than 60 years, it was observed that 25 mg amitriptyline, administered within 48 hours of rash onset and continued for 90 days, yielded a 50-percent reduction in pain at six months compared to placebo.³³ Antidepressants prescribed for HZ include amitriptyline (Elavil®), nortriptyline (Pamelor®), imipramine (Tofranil®), and desipramine (Norpramin®).¹⁵

Natural Treatment Options

Acyclovir and other antiviral drugs have provided a major advancement in the treatment of HZ and PHN. However, of growing concern is the appearance of acyclovir-resistant HSV strains among immunosuppressed patients, such as organ transplant recipients and patients with HIV/AIDS. One study revealed seven percent of immunocompromised patients had acyclovir-resistant HSV infections.³⁴

As with conventional protocols, the objective of natural therapeutics in the prevention and treatment of HZ and PHN is to facilitate healing of skin lesions, reduce pain, and prevent complications. An underlying goal for employing natural therapies is to strengthen cell-mediated immunity, thereby allowing the body's natural defense mechanisms to control the virus and prevent recurrence. Natural therapies can provide solutions to effectively manage herpes viruses, prevent and treat complications, and minimize the risk of developing viral resistance.

Dietary/Multiple-Nutrient Effects

Incidence of HZ rises sharply after age 50. One possible explanation is the potential decline in immune competence (immunosenescence) that can accompany age, making older individuals more susceptible to infection overall. Maintaining adequate nutrition is one contributing factor to ensuring healthy cell-mediated immunity.

A recent study reviewing 243 HZ cases examined whether an association exists between risk of zoster and fruit and vegetable consumption or dietary intake of select nutrients (vitamins A, B6, C, and E, and folic acid, zinc, and iron).³⁵ It was determined that individuals, particularly those over age 60, who ate less than one serving of fruit or vegetables weekly had a three-fold greater risk of zoster compared to those who ate more than three servings daily. When considered individually, consumption of select nutrients yielded no statistically significant association with HZ. However, when consumed collectively, in the form of fruits and vegetables, intake showed similar dose-related associations with HZ risk. Hence, it is thought that nutrients may act synergistically to maintain healthy immune function and, consequently, decrease zoster risk.

Vitamin A

Vitamin A functions both as a fat-soluble vitamin and a hormone, contributing to the visual pigment rhodopsin and controlling gene transcription that allows for normal proliferation and differentiation of epithelial cells. Vitamin A is a key immune modulator, involved in the synthesis of lymphocytes, neutrophils, cytokines, and immunoglobulins.³⁶

Vitamin A deficiency has been associated with increased susceptibility to numerous infectious diseases,³⁷ and is of particular concern in patients undergoing bone marrow transplants. An observational trial on 120 bone marrow transplant patients demonstrated an association between increased incidence of hyporetinolemia and increased risk of HZ infection.³⁸ This finding suggests the need to explore whether a causal relationship exists between adequate retinol stores, cell-mediated immunity, and potential activation of HZ. Interestingly, the same study also examined a possible association between low vitamin E levels and increased risk of zoster; no association was observed.

Enzyme Therapy

Prior to the introduction of acyclovir, pancreatic enzyme preparations were used effectively in Germany as a treatment for HZ. Such historical application led researchers to conduct a comparison trial.^{39,40}

In a double-blind, controlled, multicenter trial, two groups of 96 HZ patients were given either acyclovir (800 mg) or an enzyme preparation (120 mg trypsin, 40 mg chymotrypsin, and 320 mg papain) five times daily for seven days and followed for 14 days. During the course of the study, intensity of pain and reddening of skin lesions were measured. No statistically significant difference was seen between the two groups, either in pain intensity or reddening of skin lesions during the first seven days. However, on day 14 a significant decrease in skin reddening was noted in the acyclovir group; no other parameters revealed statistically significant differences. Overall, the study concluded that the enzyme preparation was just as effective as acyclovir. The suspected mechanisms of action for the enzyme formula included stimulating breakdown of immune complexes and enhancing cell-mediated immunity.^{39,40} No data was available with regard to its effect on PHN prevention.

Excessive transforming growth factor-beta (TGF- β) production is associated with immunosuppression, particularly in cancer. A small clinical trial, which included seven HZ patients with elevated serum TGF- β (>50 ng/mL), revealed oral administration of an enzyme preparation of papain, bromelain, trypsin, and chymotrypsin significantly reduced TGF- β levels ($p < 0.05$).⁴¹

Other Nutritional Considerations

Nutrients, such as vitamin C, vitamin E, lysine, and zinc have demonstrated potential in the treatment of HSV-1 and -2. Consequently, they may also be helpful against HZ, although evidence for this is primarily in the realm of anecdotal reports and speculative extrapolation. A more in-depth discussion on the use of these supplements in the management of *Herpes simplex* is provided in an article entitled, "Natural Remedies for *Herpes simplex*" by Alan Gaby, MD (*Altern Med Rev* 2006;11(2):93-101).

Botanicals with Specific Efficacy for Herpes Zoster

Capsaicin (from *Capsicum frutescens*)

Capsaicin is an alkaloid derived from cayenne pepper (*Capsicum frutescens*). A well-studied compound, capsaicin is of particular importance in the treatment of PHN because of its effect on C-fiber sensory neurons. These neurons release inflammatory neuropeptides, such as substance P, that mediate neurogenic inflammation and chemical-initiated pain.⁴² At high doses, capsaicin functions to desensitize these neurons. Clinical trials on the use of topical analgesics such as capsaicin creams have demonstrated benefit in providing temporary pain relief versus placebo in PHN.^{43,44}

Licorice (*Glycyrrhiza glabra*)

Licorice is one of the most widely used herbs in traditional medicine, spanning many generations and several continents. Its properties as an anti-inflammatory, mucoprotectant, and antiviral suggest it may have potential value in the treatment of HZ. One constituent, glycyrrhizin, inhibits virus growth and may also inactivate viral particles. It has demonstrated antiviral activity *in vitro* against various forms of herpes virus, including VZV,⁴⁵⁻⁴⁷ and induces interferon production both *in vitro* and *in vivo*.⁴⁸

When glycyrrhizin is taken orally, it is converted to glycyrrhetic acid with loss of its systemic antiviral effects.⁴⁰ However, as a topical, both glycyrrhizin and licorice may provide antiviral activity, and as such may be beneficial in cases of both HSV and HZ.⁴⁹ Further investigation of this application is warranted.

Madonna Lily (*Lilium candidum*)

In northern Italy, traditional folk medicine identifies *Lilium candidum* as an herbal treatment for HZ.⁵⁰ Bulbs of cultivated *L. candidum* have yielded successful results when fried in olive oil and applied externally as a poultice on HZ lesions. Healing properties are thought to come from the presence of eight spirostanol saponins and two furostanol saponins identified in the bulb of the plant.⁵¹ To date, however, evidence of benefit from this age-old remedy is primarily anecdotal. Rigorous scientific exploration

is needed to better understand whether this plant has antiviral properties and clinical efficacy in persons with HZ.

Reishi Mushroom (*Ganoderma lucidum*)

A few small studies have examined the effect of *Ganoderma lucidum*, either by itself or in combination with other herbs, for the treatment of HZ or PHN. One case study on two patients with HZ and two patients with PHN demonstrated administration of hot-water-soluble extracts of *Ganoderma lucidum* (36-72 g dry wt/day) had a dramatic effect on decreasing pain.⁵²

In a small clinical trial, five patients with HZ (ages 17-74 years) experienced almost complete pain relief within 10 days of treatment with an oral preparation (numbers in parentheses indicate dry weight grams per dose) of *Ganoderma lucidum* (0.75), *Wisteria floribunda* (0.38), *Trapa natans* (0.38), *Miristica agrans* (0.38), *Coix lachryma-jobi* (0.75), *Elfuinga applanata* (0.38), *Panax ginseng* (0.3), and *Punica granatum* (0.38).⁵³

Bi Phaya Yaw (*Clinacanthus nutans*)

Clinacanthus nutans, a small shrub found in Southeast Asia, has long been used in Thailand as a traditional medicine for snake and insect bites and various skin ailments. Several small studies have examined its benefit for HZ. One randomized, placebo-controlled trial was performed on 51 HZ patients using a topical preparation of *C. nutans* extract applied five times daily for 7-14 days until the lesions were healed.⁵⁴ The number of patients with lesions crusting within three days and healing within 7-10 days was significantly greater in the experimental group than the placebo group ($p < 0.01$); pain scores were significantly reduced as well. No side effects were reported with the medication.

Other Botanical Considerations

The following botanicals or plant extracts have demonstrated efficacy against HSV-1 and -2, either *in vitro* or *in vivo*. They have been highlighted in this article as possible considerations in the management of HZ, although any benefit should be noted as either speculative or anecdotal.

Honey/Propolis

Since antiquity bee products, specifically honey and propolis, have been recognized in traditional medicine as aids in wound healing. Today, their healing properties for select herpes viruses are being confirmed in both the laboratory and the examination room; they may prove to be beneficial in the management of HZ.

A small, non-blinded, cross-over study comparing topical application of honey with acyclovir cream on patients with HSV noted a significantly shorter duration of episodes and faster healing time when using a honey application versus the antiviral drug.⁵⁵ Similarly, a randomized, blinded-investigator study, comparing use of a topical propolis ointment to acyclovir and placebo for 90 patients with confirmed HSV, concluded that after 10 days a significant number of patients in the propolis group (24/30) had healed, compared to those in the acyclovir (14/30) or placebo (12/30) group.⁵⁶ These findings coincide with *in vitro* studies proposing the potential antiviral property of propolis against HSV.^{57,58}

Sangre de Grado (*Croton lechleri*)

Extracts of sangre de grado have demonstrated activity against a number of viruses, including influenza, parainfluenza, hepatitis A and B, and HSV-1 and -2. In a multicenter, double-blind, placebo-controlled study, a topical preparation of proanthocyanidin complex from sangre de grado was administered to recurrent HSV-2 lesions in AIDS patients. Viral culture revealed 50 percent of the treated group became culture negative at the end of the 21-day trial, versus 19 percent of the placebo group.⁵⁹

Aloe (*Aloe vera*)

Topical administration of *Aloe vera* has been widely used for wound healing. Aloe emodin, an anthraquinone prepared from *Aloe vera*, was shown *in vitro* to inactivate HSV-2.⁶⁰ In another study, acemannan (another ingredient of Aloe) was reported to act synergistically with acyclovir against HSV *in vitro*.⁶¹

A two-week, double-blind, placebo-controlled clinical trial on 60 male patients with HSV-2 revealed that those using a topical Aloe extract, applied three times daily for five days, had significantly shorter healing times (4.9 days) compared to individuals using placebo (12 days).⁶² Furthermore, 66.7 percent of subjects in the treatment group had resolution of their symptoms within two weeks compared to 6.7 percent of subjects on placebo.

St John's wort (*Hypericum perforatum* and spp)

St John's wort is widely known in traditional medicine as an effective treatment for viral infections and afflictions related to the nerves. Regarding its effect on herpes viruses, several studies show promise. *Hypericum* species have been observed *in vitro* to demonstrate potent antiviral activity against HSV-1.⁶³⁻⁶⁵ In addition, two double-blind, placebo-controlled studies have demonstrated efficacy of orally administered *Hypericum perforatum* extract against HSV.⁶⁶

Other Treatment Options

Traditional Chinese Medicine (TCM)

Acupuncture has long been regarded as an effective therapy for pain management. Although several cases have been documented on its use in HZ and PHN, sample sizes have been small. Nonetheless, positive reports should encourage further investigation. One study documented a case of a 52-year-old male diagnosed with PHN who was successfully treated after four treatments using a combination of acupuncture and moxibustion.⁶⁷ The patient's pain, which extended from the right flank to the inguinal region, was reduced from a status of severe to that of mild discomfort, allowing him to return to work.

Preliminary studies demonstrate Chinese medicine may show promise when used in conjunction with conventional therapies in the management of PHN. One non-randomized, uncontrolled study on 56 patients, using a five-pronged therapy combination of acupuncture, nerve block injection, cupping and bleeding, meditation, and Chinese herbs, reported an average of 72.1 percent reduction in pain.⁶⁸

TENS

Use of Transcutaneous Electrical Nerve Stimulation (TENS) therapy has been beneficial in the management of PHN.^{32,69,70} In one review, the use of combination therapy consisting of amitriptyline, topical capsaicin, and TENS was recommended for the treatment of PHN over antiviral therapy.⁷¹

Conclusions

Many options are available to the clinician for the treatment of HZ and PHN, albeit with variable degrees of success.

Antiviral agents, such as acyclovir, valacyclovir, and famciclovir, have been shown to reduce both the pain and healing time of skin lesions associated with HZ, but have marginal success in preventing and treating PHN. Corticosteroids may be used for pain management in HZ, but do not seem to be effective in prevention of PHN. Analgesics provide effective temporary pain relief for both HZ and PHN. Nerve block injections offer more long-term pain relief in both conditions, provided they are administered early in the course of the disease. Tricyclic antidepressants may provide pain relief in cases of PHN, but require at least three months for positive effects.

The potential for antiviral resistance, particularly in immunosuppressed individuals, is of growing concern, as this group is at greater risk of developing HZ and PHN. Furthermore, increased cost of antiviral therapy can present a financial obstacle for at-risk individuals to obtain conventional medication. These issues underscore the need to investigate and identify alternative therapeutic options.

Although vitamin A deficiency appears to be associated with increased susceptibility to HZ in immunosuppressed individuals, further investigation is needed to determine whether a causal relationship exists. Enzyme therapy may serve as an effective alternative to acyclovir. Topical use of capsaicin in the management of pain has been shown to be effective in PHN, while topical applications of licorice extract, Madonna lily bulb, and *C. nutans* have been used in the treatment of skin lesions associated with HZ; further investigation is needed to determine clinical efficacy. Small case studies using hot-water-soluble extracts of reishi mushroom by itself or in combination with other herbs indicate potential benefit in both

HZ and PHN. As with other herbs mentioned, further rigorous investigation is needed to determine clinical relevance.

A number of other natural substances warrant investigation in the treatment of HZ by virtue of demonstrated efficacy for *Herpes simplex* viruses. These include honey and propolis, sangre de grado, aloe, Hypericum, lysine, zinc, and vitamins C and E.

TCM and TENS, in conjunction with conventional therapeutics, may be beneficial in the prevention and treatment of PHN.

References

- National Institute of Allergy and Infectious Disease, 2003. <http://content.nhiondemand.com/psv/HC2.asp?objID=100635&cType=hc> [Accessed May 8, 2006]
- Gnann JW Jr, Whitley RJ. Clinical practice. Herpes zoster. *N Engl J Med* 2002;347:340-346.
- National Institute of Neurological Disorders and Stroke (NINDS), 1999. <http://content.nhiondemand.com/psv/HC2.asp?objID=100635&cType=hc> [Accessed May 8, 2006]
- Hope-Simpson RE. The nature of herpes zoster: a long term study and a new hypothesis. *Proc R Soc Med* 1965;58:9-20.
- Katz J, Cooper EM, Walther RR, et al. Acute pain in herpes zoster and its impact on health-related quality of life. *Clin Infect Dis* 2004;39:342-348.
- Whitley RJ. Varicella-zoster virus infections. In: Fauci AS, Braunwald E, Isselbacher KJ, et al, eds. *Harrison's Principles of Internal Medicine*. 14th ed. New York, NY: McGraw Hill; 1998:1086-1089.
- Berkow R, Fletcher AJ, eds. Chickenpox (varicella). *The Merck Manual*. 16th ed. Rahway, NJ: Merck Research Laboratories; 1992:2175.
- Samuelson J, von Lichtenberg F. Infectious diseases. In: Cotran R, Kumar V, Robbins S, eds. *Robbins Pathologic Basis of Disease*. 5th ed. Philadelphia, PA: WB Saunders; 1994:349.
- Schmader KE. Epidemiology and impact on quality of life of postherpetic neuralgia and painful diabetic neuropathy. *Clin J Pain* 2002;18:350-354.
- Gnann JW, Whitley RJ. Natural history and treatment of varicella-zoster in high-risk populations. *J Hosp Infect* 1991;18:317-329.
- Gupta LK, Kuldeep CM, Mittal A, Singhal H. Multidermatomal herpes zoster in an immunocompetent female. *Indian J Dermatol Venereol Leprol* 2005;71:210-211.
- Shaikh S, Ta CN. Evaluation and management of herpes zoster ophthalmicus. *Am Fam Physician* 2002;66:1723-1730.
- Berkow R, Fletcher AJ, eds. Herpes zoster oticus. *The Merck Manual*. 16th ed. Rahway, NJ: Merck Research Laboratories; 1992:2338.
- Awasthi D. Ramsay-Hunt Syndrome. *eMedicine*. www.emedicine.com/neuro/topic420.htm [Accessed March 24, 2006]
- Stankus SJ, Dlugopolski M, Packer D. Management of herpes zoster (shingles) and postherpetic neuralgia. *Am Fam Physician* 2000;61:2437-2444, 2447-2448.
- Berkow R, Fletcher AJ, eds. Herpes zoster. *The Merck Manual*. 16th ed. Rahway, NJ: Merck Research Laboratories; 1992:203.
- Mounsey AL, Matthew LG, Slawson DC. Herpes zoster and postherpetic neuralgia: prevention and management. *Am Fam Physician* 2005;72:1075-1080.
- Wood MJ, Shukla S, Fiddian AP, Crooks RJ. Treatment of acute herpes zoster: effect of early (< 48 h) versus late (48-72 h) therapy with acyclovir and valaciclovir on prolonged pain. *J Infect Dis* 1998;178:S81-S84.
- Beutner KR, Friedman DJ, Forszpaniak C, et al. Valaciclovir compared with acyclovir for improved therapy for herpes zoster in immunocompetent adults. *Antimicrob Agents Chemother* 1995;39:1546-1553.
- Tyring S, Barbarash RA, Nahlik JE, et al. Famciclovir for the treatment of acute herpes zoster: effects on acute disease and postherpetic neuralgia. A randomized, double-blind, placebo-controlled trial. Collaborative Famciclovir Herpes Zoster Study Group. *Ann Intern Med* 1995;123:89-96.
- Shafraan SD, Tyring SK, Ashton R, et al. Once, twice, or three times daily famciclovir compared with aciclovir for the oral treatment of herpes zoster in immunocompetent adults: a randomized, multicenter, double-blind clinical trial. *J Clin Virol* 2004;29:248-253.
- Crooks RJ, Jones DA, Fiddian AP. Zoster-associated chronic pain: an overview of clinical trials with acyclovir. *Scand J Infect Dis Suppl* 1991;80:62-68.
- Whitley RJ, Weiss H, Gnann JW Jr, et al. Acyclovir with and without prednisone for the treatment of herpes zoster. A randomized, placebo-controlled trial. The National Institute of Allergy and Infectious Diseases Collaborative Antiviral Study Group. *Ann Intern Med* 1996;125:376-383.
- Wood MJ, Johnson RW, McKendrick MW, et al. A randomized trial of acyclovir for 7 days or 21 days with and without prednisolone for treatment of acute herpes zoster. *N Engl J Med* 1994;330:896-900.

25. Kochar DK, Agarwal RP, Joshi A, Kumawat BL. Herpes zoster and post-herpetic neuralgia – a clinical trial of aspirin in chloroform for anodyne. *J Assoc Physicians India* 1998;46:337-340.
26. Balakrishnan S, Bhushan K, Bhargava VK, Pandhi P. A randomized parallel trial of topical aspirin-moisturizer solution vs. oral aspirin for acute herpetic neuralgia. *Int J Dermatol* 2001;40:535-538.
27. Tajti J, Szok D, Vecsei L. Topical acetylsalicylic acid versus lidocaine for postherpetic neuralgia: results of a double-blind comparative clinical trial. *Neurobiology (Bp)* 1999;7:103-108.
28. Gildeen DH, Kleinschmidt-DeMasters BK, LaGuardia JJ, et al. Neurologic complications of the reactivation of varicella-zoster virus. *N Engl J Med* 2000;342:635-645.
29. Watson CP, Babul N. Efficacy of oxycodone in neuropathic pain: a randomized trial in postherpetic neuralgia. *Neurology* 1998;50:1837-1841.
30. Raja SN, Haythornthwaite JA, Pappagallo M, et al. Opioids versus antidepressants in postherpetic neuralgia: a randomized, placebo-controlled trial. *Neurology* 2002;59:1015-1021.
31. Herpes zoster (shingles). ThePhysicians.com. www.thephysicians.com/herpeszoster.html [Accessed March 27, 2006]
32. Johnson RW. Herpes zoster and postherpetic neuralgia. Optimal treatment. *Drugs Aging* 1997;10:80-94.
33. Bowsher D. The effects of pre-emptive treatment of postherpetic neuralgia with amitriptyline: a randomized, double-blind, placebo-controlled trial. *J Pain Symptom Manage* 1997;13:327-331.
34. Stranska R, Schuurman R, Nienhuis E, et al. Survey of acyclovir-resistant *Herpes simplex* virus in the Netherlands: prevalence and characterization. *J Clin Virol* 2005;32:7-18.
35. Thomas SL, Wheeler JG, Hall AJ. Micronutrient intake and the risk of herpes zoster: a case-control study. *Int J Epidemiol* 2006;35:307-314.
36. Semba RD. The role of vitamin A and related retinoids in immune function. *Nutr Rev* 1998;56: S38-S48.
37. Semba RD. Vitamin A and immunity to viral, bacterial and protozoan infections. *Proc Nutr Soc* 1999;58:719-727.
38. High KP, Legault C, Sinclair JA, et al. Low plasma concentrations of retinol and alpha-tocopherol in hematopoietic stem cell transplant recipients: the effect of mucositis and the risk of infection. *Am J Clin Nutr* 2002;76:1358-1366.
39. Murray M. *Encyclopedia of Nutritional Supplements*. Rocklin, CA: Prima Publishing; 1996:398.
40. Billigmann P. Enzyme therapy – an alternative in treatment of herpes zoster. A controlled study of 192 patients. *Fortschr Med* 1995;113:43-48. [Article in German]
41. Desser L, Holomanova D, Zavadova E, et al. Oral therapy with proteolytic enzymes decreases excessive TGF-beta levels in human blood. *Cancer Chemother Pharmacol* 2001;47:S10-S15.
42. Bone K, Mills S. *Principles and Practice of Phytotherapy*. Edinburgh, UK: Churchill Livingstone; 2000:41.
43. Bernstein JE, Korman NJ, Bickers DR, et al. Topical capsaicin treatment of chronic postherpetic neuralgia. *J Am Acad Dermatol* 1989;21:265-270.
44. Watson CP, Tyler KL, Bickers DR, et al. A randomized vehicle-controlled trial of topical capsaicin in the treatment of postherpetic neuralgia. *Clin Ther* 1993;15:510-526.
45. Pompei R, Flore O, Marccialis MA, et al. Glycyrrhizic acid inhibits virus growth and inactivates virus particles. *Nature* 1979;281:689-690.
46. Pompei R, Pani A, Flore O, et al. Antiviral activity of glycyrrhizic acid. *Experientia* 1980;36:304.
47. Baba M, Shigeta S. Antiviral activity of glycyrrhizin against varicella-zoster virus *in vitro*. *Antiviral Res* 1987;7:99-107.
48. Abe N, Ebina T, Ishida N. Interferon induction by glycyrrhizin and glycyrrhetic acid in mice. *Microbiol Immunol* 1982;26:535-539.
49. Bone K, Mills S. *Principles and Practice of Phytotherapy*. Edinburgh, UK: Churchill Livingstone; 2000:470.
50. Pieroni A. Medicinal plants and food medicines in the folk traditions of the upper Lucca Province, Italy. *J Ethnopharmacol* 2000;70:235-273.
51. Mimaki Y, Satou T, Kuroda M, et al. New steroidal constituents from the bulbs of *Lilium candidum*. *Chem Pharm Bull (Tokyo)* 1998;46:1829-1832.
52. Hijikata Y, Yamada S. Effect of *Ganoderma lucidum* on postherpetic neuralgia. *Am J Chin Med* 1998;26:375-381.
53. Hijikata Y, Yasuhara A, Sahashi Y. Effect of an herbal formula containing *Ganoderma lucidum* on reduction of herpes zoster pain: a pilot clinical trial. *Am J Chin Med* 2005;33:517-523.
54. Sangkitporn S, Chaiwat S, Balachandra K, et al. Treatment of herpes zoster with *Clinacanthus nutans* (bi phaya yaw) extract. *J Med Assoc Thai* 1995;78:624-627.
55. Al-Waili NS. Topical honey application vs. acyclovir for the treatment of recurrent *Herpes simplex* lesions. *Med Sci Monit* 2004;10:MT94-MT98.

56. Vynograd N, Vynograd I, Sosnowski Z. A comparative multi-centre study of the efficacy of propolis, acyclovir and placebo in the treatment of genital herpes (HSV). *Phytomedicine* 2000;7:1-6.
57. Amoros M, Lurton E, Boustie J, et al. Comparison of the anti-*Herpes simplex* virus activities of propolis and 3-methyl-but-2-enyl caffeate. *J Nat Prod* 1994;57:644-647.
58. Debiaggi M, Tateo F, Pagani L, et al. Effects of propolis flavonoids on virus infectivity and replication. *Microbiologica* 1990;13:207-213.
59. Williams JE. Review of antiviral and immunomodulating properties of plants of the Peruvian rainforest with particular emphasis on una de gato and sangre de grado. *Alt Med Rev* 2001;6:567-579.
60. Sydiskis RJ, Owen DG, Lohr JL, et al. Inactivation of enveloped viruses by anthraquinones extracted from plants. *Antimicrob Agents Chemother* 1991;35:2463-2466.
61. Kahlon JB, Kemp MC, Yawei N, et al. *In vitro* evaluation of the synergistic antiviral effects of acemannan in combination with azidothymidine and acyclovir. *Mol Biother* 1991;3:214-223.
62. Syed TA, Afzal M, Ashfaq AS, et al. Management of genital herpes in men with 0.5% Aloe vera extract in a hydrophilic cream: a placebo-controlled double-blind study. *J Dermatol Treat* 1997;8:99-102.
63. Vijayan P, Raghu C, Ashok G, et al. Antiviral activity of medicinal plants of Nilgiris. *Indian J Med Res* 2004;120:24-29.
64. Sokmen A, Jones BM, Erturk M. Antimicrobial activity of extracts from the cell cultures of some Turkish medicinal plants. *Phytother Res* 1999;13:355-357.
65. Taylor RS, Manandhar NP, Hudson JB, Towers GH. Antiviral activities of Nepalese medicinal plants. *J Ethnopharmacol* 1996;52:157-163.
66. Koytchev R, Alken RG, Dundarov S. Hypericum extract LI 160 for the therapy of *Herpes simplex* genitalis and labialis: results of two placebo-controlled, randomized, double-blind, clinical trials. *Z Phytother* 1999;20:92. [Article in German]
67. Sumita K, Kogure K, Sasaki T. Acupuncture therapy of depression (2): theory and therapy of depression in traditional Oriental medicine. *J Jpn Acup Moxibust* 1988;47:6-13. [Article in Japanese]
68. Hui F, Cheng A, Chiu M, Vayda E. Integrative approach to the treatment of postherpetic neuralgia: a case series. *Altern Med Rev* 1999;4:429-435.
69. Wulf H, Maier C, Schele HA. The treatment of zoster neuralgia. *Anaesthesist* 1991;40:523-529. [Article in German]
70. Devulder JE. Postherpetic ophthalmic neuralgia. *Bull Soc Belge Ophthalmol* 2002;285:19-23.
71. Carmichael JK. Treatment of herpes zoster and postherpetic neuralgia. *Am Fam Physician* 1991;44:203-210.