

Natural Treatment of Chronic Rhinosinusitis

Steve Helms, ND and Alan L. Miller, ND

Abstract

Chronic rhinosinusitis (CRS) is one of the most common long-term illnesses in the United States, affecting approximately 14 percent of the population. CRS is a challenging condition to treat, partly due to its multifaceted, poorly understood pathophysiology. Treatment goals include maintaining open drainage and decreasing inflammation while improving tissue integrity and limiting causative factors. This review covers the etiology, pathology, and diagnosis of CRS, as well as mainstream and alternative treatments. Discussion of alternative therapeutics includes nutrients and botanicals (ascorbic acid, bromelain, N-acetylcysteine, quercetin, undecylenic acid, and *Urtica dioica* and other herbal medicines) and procedures (nasal irrigation and nasosympatico treatments). The influences of diet and air quality on CRS are also discussed. (*Altern Med Rev* 2006;11(3):196-207)

Introduction

Chronic rhinosinusitis (CRS) is one of the most common chronic illnesses in the United States, with an estimated prevalence of 14 percent in the population. CRS more commonly develops in allergic patients and asthmatics (up to 30% and 43%, respectively).¹ In 2003, the mean medical cost was \$921 per patient, with a total economic cost of \$1,539 per patient, which includes an average of 4.8 missed work days annually.² The main reason for this burden is the multifaceted pathophysiology of CRS and the subsequent lack of consistently effective treatment.

Chronic rhinosinusitis involves the physiological disruption of the mucus membranes from particulates, allergens, infection, and immune system dysregulation. The term rhinosinusitis refers to inflammation of the contiguous tissues of the upper respiratory tract, where insult to the nasal mucosa also affects adjacent sinus tissue. Sinus pain may

distinguish sinusitis from rhinitis, although it is agreed that 12 weeks of sinus inflammation is required for a diagnosis of CRS.³

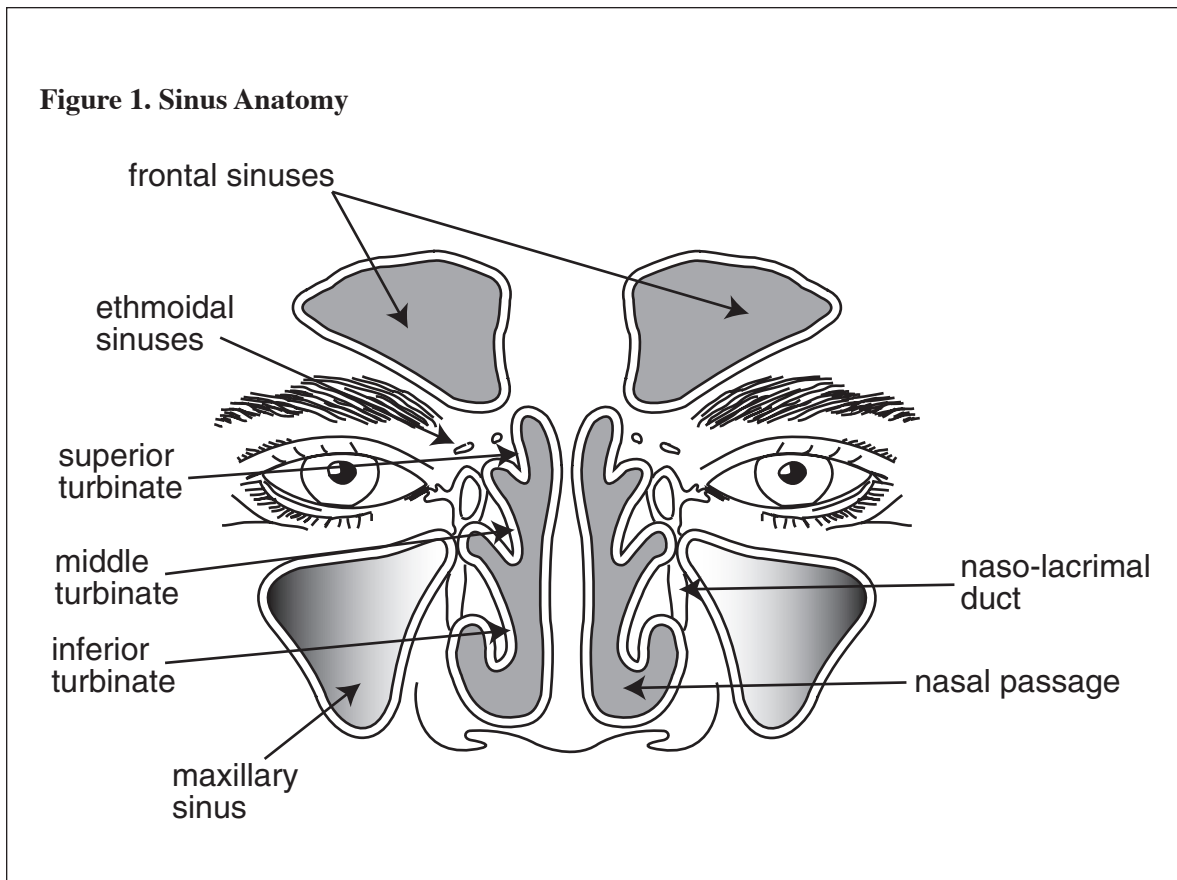
The four pairs of sinuses (maxillary, frontal, ethmoidal, and sphenoidal) are partially enclosed cavities open to the nasal passages through small holes (ostea or meatus) (Figure 1). The warm, moist sinus environment they create is speculated to aid olfaction, increase vocal resonance, reduce the bony weight of the skull, and protect intracranial structures from trauma.⁴ The ciliated epithelium, in coordination with mucus production, continually remove waste from the sinuses. However, when the ostea are closed, drainage is impeded and pressure increases, causing pain. With reduced sinus drainage comes an increased risk of microbial overgrowth within the mucus layer and in sinus tissue.

Etiology

Chronic sinusitis is a sequela of acute sinusitis, which in turn can be a complication of allergic rhinitis or a viral upper respiratory infection (Figure 2).⁵ This evolution begs two pivotal questions. First, why does acute rhinosinusitis, which appears as part of the normal clinical course of the common cold,⁶ not always transition into CRS? Second, why don't all allergic rhinitis sufferers experience chronic rhinosinusitis? Whether due to anatomical factors, physiological factors, immune system involvement, or infectious agents, the common thread in CRS is a disruption of the normal production of sinus fluid and its outflow from the sinus cavities.

Steve Helms, ND – 2001 graduate of the Southwest College of Naturopathic Medicine; Private practice in Sandpoint, Idaho.

Alan L. Miller, ND – 1989 graduate of Bastyr University; Technical advisor, Thorne Research; Senior editor, *Alternative Medicine Review*.
Correspondence address: Thorne Research, PO Box 25, Dover, ID 83825.
Email: alanm@thorne.com



Anatomical Factors

Anatomical sinus abnormalities are common in the general population, but do not appear specific to sinusitis sufferers. Reversible sinus abnormalities are often seen with the common cold. Some of these abnormalities, noted on CT scan, include septal deviation (19.5%), additional air cells within the sinuses (45%), and enlargement or ballooning of nasal turbinates (11-16%).⁶

Mucus and Mucociliary Transport

The mucus-lined nasal and sinus passages collect pollen, dust, dirt, fungal spores, and other particulates from the air. Mucus production is balanced with the sweeping action of ciliated epithelium, which facilitates drainage and particulate removal.⁷ The consistency of mucus (a complex of water, sugar, lipids, and protein) can change from a planar structure to a globular structure that is not as effective at covering mucosal membranes and collecting particulates.^{8,9} When the mucus no longer protects the epithelial lining there is increased incidence of irritation, inflammation, and allergic potential.¹⁰ Viscous mucus is

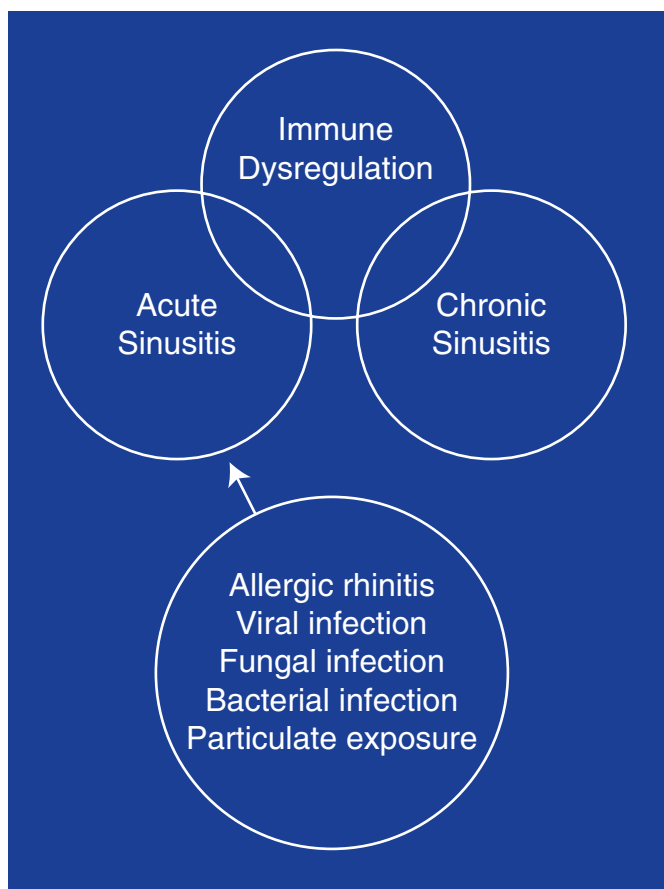
more difficult to clear from the sinuses and nasal mucosa, which is complicated by the fact that chronic sinusitis sufferers have significantly reduced mucociliary clearance compared to normal controls.¹¹ Sinusitis symptomatology may, therefore, be created and sustained by changes in mucus structure and reduced mucociliary transport.

Chronic Sinusitis and the Fungal Connection – Allergic Fungal Sinusitis

Chronic sinusitis results in local non-invasive tissue destruction¹² by activated granulocytes that produce reactive oxygen species, including hydroxyl radicals, superoxide anions, and hydrogen peroxide.¹³ Increased inflammatory cytokine production is also common, with elevated interleukin (IL)-1alpha, IL-1beta, IL-5, IL-6, IL-8, tumor necrosis factor-alpha (TNF- α), and intercellular adhesion molecule-1.¹⁴

Bacterial, fungal, and viral infections increase inflammatory cytokine levels; however, current data indicate the majority of chronic rhinosinusitis patients fit the diagnostic criteria for allergic fungal sinusitis (AFS).¹⁵ Through new collection and

Figure 2. Progression to Chronic Rhinosinusitis



culture techniques, researchers have found fungal colonies are ubiquitous in AFS patients as well as asymptomatic controls. The difference between the simple appearance of fungi in nasal/sinus secretions and the debilitating symptomatology of AFS appears to be the immune system's reaction to the presence of fungi.¹⁶⁻¹⁹ A universal component of AFS is the presence of "allergic mucin," which contains abnormally high amounts of both fungi and eosinophils.¹⁹⁻²³ In addition, Collins et al found AFS patients were significantly more likely to have fungal-specific IgE in sinus mucin, which was correlated to a systemic fungal allergy ($p=0.05$).¹⁶

Atopic children also have been found to have a higher incidence of AFS.²⁰ Asthmatics tend to have concomitant rhinosinusitis, and researchers have found many asthma patients exhibit poor asthma control until the chronic sinusitis is controlled.^{24,25}

Infectious Components

Acute sinusitis is most commonly caused by viruses²⁶ without bacterial co-infection²⁷ and is a known precursor to CRS. Acute rhinosinusitis, confirmed by CT scan, is noted as part of the normal clinical course of the common cold, but acute bacterial sinusitis has been reported to follow the common cold in only 0.5-5.0 percent of cases.⁶ Rhinovirus infection, which is involved in nearly half of common cold diagnoses,²⁸ induces mucus hypersecretion²⁹ and may promote CRS by reducing mucociliary clearance in susceptible populations.

In chronic, non-allergic sinusitis, electron microscopy reveals the lack of bacterial invasion or formation of phagosomes containing bacteria.³⁰ Interestingly, in a Cochrane Database of Systematic Reviews analysis of bacterial sinusitis, no randomized clinical trials were found that examined sinus cultures before and after antibiotic treatment, even though antibiotics are the most commonly used therapeutic tool in CRS.³¹

Although allergic fungal sinusitis is emerging as a common cause of CRS, invasive fungal sinus infections rarely occur in immunocompetent individuals.³² Invasive fungal infection requires emergency care and can lead to death. More common, and less lethal, is a condition called sinus mycetoma, or fungal ball. Occurring in more humid areas and often coupled with nasal polyps and loosely associated with atopics,³² fungal ball is a dense conglomeration of hyphae that grows to fill the sinus cavity (generally the maxillary sinus), causing pressure and resultant pain that is relieved by removal, aeration, and drainage, commonly without antifungal treatment.³³

Pathology

Thickened nasal walls, engorged turbinates, and osteal occlusion characterize CRS. These reversible abnormalities of the nasal/sinus passages and ostea appear to be due to a progressive feed-forward cycle initiated by irritation and perpetuated by inflammatory mediators. Whatever the cause of the inciting irritation, local cells release cytokines that act as attractants for immune cells. Other cytokines (especially histamine in an allergic response) trigger dilation of local venules and capillaries, providing ease of access for leukocytes to enter tissue. This allows fluid

to leave the vascular compartment, accounting for the observed signs of swelling, redness, and heat. Continued signaling initiates gross tissue edema. As tissue swelling blocks osteal drainage, airflow becomes inadequate, intrasinus pressure increases,³⁴ and blood flow to the tissues is significantly reduced.³⁵ In order to maintain the balance of gas exchange, the maxillary ostea must be open at least 5 mm².³⁶ Greater constriction leads to pain as increasing sinus pressure stimulates sensory receptors.

Along with sinus irritation and inflammation are associated reductions in nutrition and waste transport. The epithelial cilia become ineffective in removing mucin as well as microbial and cellular substrate. Impaired epithelial function in CRS is noted by significantly reduced ATP content³⁷ and glucose concentration.³⁵ Conversely, goblet cell hypersecretion is noted by significantly increased Na/K-ATPase.³⁸ Drainage is impaired as mucin composition significantly changes in chronic sinusitis, resulting in increased viscosity and the inability to successfully drain fluid from the extracellular space.^{39,40}

Tissue infiltration of activated eosinophils has been noted in sinusitis,⁴¹ along with deposition of toxic major basic protein onto the epithelium in CRS.⁴² Inflammation in CRS is also perpetuated by elevated levels of lactic acid generated from infiltrating leukocytes^{37,43} and the release of histamine from mast cells.⁴⁴

Diagnosis

Diagnosis of sinusitis is based on symptom chronicity. Acute sinusitis is defined as inflammation for less than eight weeks in children and 12 weeks in adults, while chronic sinusitis is defined as persisting more than eight or 12 weeks, respectively.⁴

Viral rhinosinusitis usually resolves within seven days without intervention.²⁶ Bacterial rhinosinusitis is suggested by maxillary tooth or facial pain (especially unilateral) and unilateral maxillary sinus tenderness.²⁶ Purulent nasal discharge and worsening symptoms after initial improvement are also reliable clues of bacterial sinusitis, but are not confirmatory. Elevated eosinophil counts are also commonly seen in bacterial sinusitis as well as AFS.⁴¹ Allergic predisposition can be determined from history.

Unfortunately, a simple, reliable, and convenient method of diagnosis of CRS is unavailable. Pain on sinus percussion is non-specific for sinusitis. Visualization can only confirm tissue erythema and edema, while endoscopy can provide evidence of occluded ostea.⁴

The benefit of imaging in diagnosis of chronic sinusitis is limited, as X-ray and CT scans are nonspecific. Magnetic resonance imaging (MRI) for chronic sinusitis is plagued by false positives, although it appears to complement CT scans in confirming sinus mycetoma (fungal ball), invasive fungal sinusitis, or suspected sinonasal cancer – the latter of which has an annual incidence of 1:100,000.⁴⁵

The difficulty with imaging procedures is not due to poor soft tissue recognition, but lack of specificity to CRS, as there is an array of conditions with similar presentations. For example, 40 percent of asymptomatic adults and 65 percent of adults with minor colds show abnormalities on sinus CT scan.⁶ Furthermore, even a compelling finding like complete opacification of the sphenoid or frontal sinus is not associated with increased clinical severity.⁴⁶ The current recommendation is to be judicious and avoid conclusive assessments from imaging.

Conventional Treatment

Conventional medical treatment of sinusitis includes antibacterials and corticosteroids, with adjunctive care involving decongestants and antihistamines. Surgical drainage by endoscopy of the osteomeatal complex (confluence for the drainage of sphenoid, anterior ethmoid, and maxillary sinuses) often can help restore mucociliary clearance and normal airflow.⁴

Although antibiotics are often used in the treatment of CRS, they have been shown to offer no advantage over placebo in acute maxillary sinusitis. A 2006 Cochrane Review meta-analysis of 49 trials reported insignificant cure rates across antibiotic classes.³¹ Oral corticosteroids are commonly given for 2-4 weeks to blunt the inflammatory response.³² Decongestants and antihistamines often provide beneficial symptomatic relief.

Systemic antifungal agents (itraconazole and voriconazole) demonstrate good *in vitro* activity against dematiaceous molds and *Aspergillus* fungal

species, but have not been accepted as a therapy in noninvasive sinusitis.^{19,47} However, the topical antifungal, amphotericin B, has recently shown significant clinical efficacy in CRS when used as a nasal spray twice daily for two months.⁴⁸ Another study utilizing amphotericin B nasal spray found worsening of symptoms in the CRS group compared to controls.⁴⁹ Oral antifungals are beginning to be examined, and in a 2005 study high-dose oral terbinafine did not improve CRS symptoms or radiographic sinus appearance in 41 fungus-positive patients. The authors of the study thought the drug might not have reached a high enough concentration in the nasal mucus to be helpful.⁵⁰

Allergen immunotherapy induces immune competence through introduction of an allergen in graduated concentrations over time from an initially minute exposure. This treatment holds promise for reduced relapse in allergic fungal sinusitis, as was evidenced in a 1998 study in which specific immunotherapy with fungal antigens significantly improved objective mucosal findings and patient quality of life. Immunotherapy also reduced patient reliance on topical systemic corticosteroid medications.⁵¹

Sino-nasal polyps are a common finding in late-stage chronic sinusitis. A small French study investigated four patients with nasal polyps for allergy to *Candida albicans*, then treated all four with *Candida* antigen immunotherapy. Symptomatic improvements of 60-80 percent were seen, as well as a reduction in viral triggers and seasonal symptoms.⁵²

Three-month, low-dose macrolide antibiotic therapy has shown potential promise in chronic sinusitis, although the studies have been small, uncontrolled clinical trials. Macrolides have anti-inflammatory activity in addition to antibacterial action. Macrolides appear to predominantly influence the neutrophilic – but not the eosinophilic – population, therefore benefiting chronic sinusitis without eosinophilia.^{53,54} Repeated nasal cultures during macrolide therapy are advocated because of the potential for the development of macrolide-resistant bacterial strains.⁵⁵

Alternative Medicines

Ascorbic Acid

Vitamin C is maintained in phagocytes and lymphocytes at 100 times greater concentration than the plasma⁵⁶ and inhibits histamine secretion by white blood cells.⁵⁷ As plasma ascorbic acid levels decrease, histamine levels increase significantly. Oral dosing of vitamin C appears to reliably lower blood histamine levels.⁵⁸

A 2004 prospective trial examined blood levels of various vitamins and minerals in children with CRS compared to healthy, age-matched controls. Vitamin C, vitamin E, copper, and zinc levels were significantly lower in the chronic sinusitis group compared to controls.¹³ In a clinical trial in which intranasal vitamin C was used to treat allergic rhinitis, 48 subjects received either ascorbic acid solution (n=27) or placebo (n=21) sprayed into the nose three times daily. After two weeks, 74 percent of subjects treated with the ascorbate solution exhibited a decrease in nasal secretions, blockage, and edema, compared to 24 percent of controls.⁵⁹

Bromelain

Bromelain, a proteolytic enzyme complex from pineapple, has commonly been used in sinusitis as an anti-inflammatory and mucolytic. A 2005 German clinical study found children with acute sinusitis exhibited statistically significant faster symptom recovery (p=0.005) compared with standard treatment,⁶⁰ confirming clinical findings from the 1960s.⁶¹ One 1967 study reported 85 percent of sinusitis patients receiving bromelain obtained complete resolution of inflammation of the nasal mucosa (p<0.05) compared to 40 percent in the placebo group.⁶²

Bromelain appears to thin nasal secretions and has been shown to be an effective mucolytic agent in other respiratory tract diseases.⁶³ This is in addition to bromelain's proteolytic activity at inflammatory sites, which is thought to promote the inhibition of pro-inflammatory prostaglandin biosynthesis and the initiation of prostaglandin E1 accumulation (which inhibits the release of polymorphonuclear leukocyte lysosomal enzymes).⁶⁴⁻⁶⁶ Bromelain oral dosage is typically 500-1,000 mg/day, with up to 2,000 mg/day commonly used.⁶⁷

N-acetylcysteine (NAC)

The effectiveness of NAC for sinusitis is primarily attributed to its mucolytic activity. NAC's sulfhydryl group cleaves disulfide bonds in mucoproteins, causing mucus to be subsequently broken into smaller, less viscous units (Figure 3).⁶⁸ NAC has been noted to increase the mucociliary clearance rate by 35 percent, with no improvement from placebo.⁶⁹ This activity is thought to be due to thinning of secretions rather than reported stimulation of ciliary beating.⁷⁰ In an *in vitro* rabbit model, using mucus from human chronic sinusitis sufferers, NAC decreased the viscoelasticity of nasal mucus.⁷¹

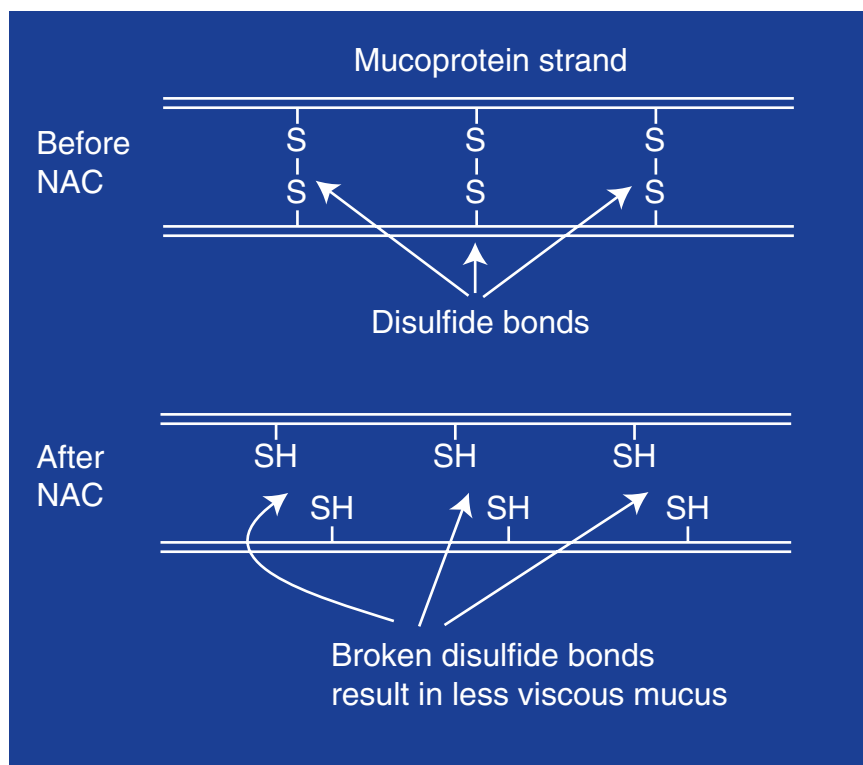
The typical adult oral dose for NAC as a mucolytic agent is 600-1,500 mg daily in three divided doses. NAC is generally safe and well tolerated, even at high doses. The most common side effects associated with high oral doses are nausea, vomiting, and other gastrointestinal disturbances.^{72,73}

Quercetin

Quercetin is widely distributed in the plant kingdom and is the most abundant of the flavonoid molecules. Quercetin's anti-inflammatory activity appears to be due to its antioxidant and inhibitory effects on inflammation-producing enzymes. Quercetin inhibits cyclooxygenase and lipoxygenase, which regulate the production of the inflammatory mediators – leukotrienes and prostaglandins.^{74,75} It also directly scavenges oxygen radicals,⁷⁶ inhibits xanthine oxidase, and inhibits lipid peroxidation *in vitro*.^{77,78}

An important characteristic of quercetin in CRS is its ability to stabilize mast cells, which inhibits release of histamine.⁷⁸⁻⁸⁰ Clinically, quercetin appears to be therapeutically similar to the synthetic flavonoid analogue cromolyn sodium. Quercetin has also displayed the ability to inhibit histamine release after stimulation by IgE-dependent ligands.⁸¹

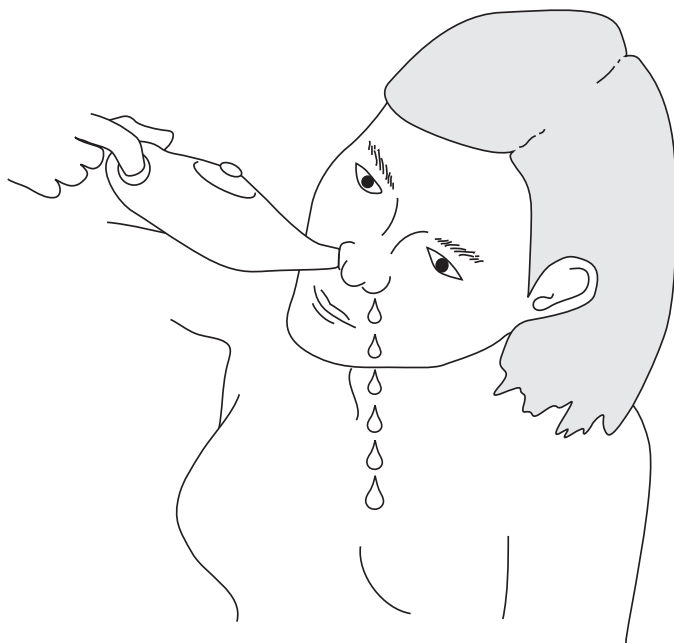Figure 3. Mucolytic Activity of NAC



An oral dose of 400-500 mg three times per day is typically used, while the water-soluble quercetin molecule, quercetin chalcone, might be used in smaller doses, typically 250 mg three times daily.

Undecylenic acid

Undecylenic acid (10-undecanoic acid) is an eleven-carbon monounsaturated fatty acid ($C_{11}H_{20}O_2$) found in the skin's sebaceous secretions. It has been used in oral and topical preparations as an antifungal for over 60 years. The zinc salt of undecylenic acid (zinc undecylenate) was an ingredient in many topical over-the-counter antifungal preparations until recent years, when other more potent topical antifungals were introduced.⁸² Large-scale clinical studies have not been conducted; however, undocumented case reports confirm undecylenic acid's efficacy in sinusitis. Undecylenic acid's particular benefit in allergic fungal sinusitis may be through reduced burden of fungi in the sinuses, as well as decreased intestinal fungal dysbiosis.

Figure 4. Nasal Irrigation

Undecylenic acid inhibits morphogenesis of *Candida albicans*. It appears to interfere with fatty acid biosynthesis, which inhibits germ tube (hyphae) formation and disrupts the pH in the yeast cell.⁸³ Undecylenic acid appears to have the greatest antifungal activity of the medium-chain fatty acids and has been shown to be approximately six times more effective as an antifungal than caprylic acid.⁸⁴

The adult dosage of undecylenic acid is usually 450-750 mg daily in three divided doses.

Urtica dioica (Stinging Nettle)

Urtica dioica, commonly known as stinging nettle, has been traditionally used to treat allergies. Nettle contains histamine and serotonin (6.1 ng and 33.25 pg per nettle hair, respectively⁸⁵), as well as acetylcholine in the plant's stinging hairs.^{86,87}

There are no clinical studies on the use of *Urtica dioica* in sinusitis; however, a randomized, double-blind clinical trial using freeze-dried *Urtica dioica* (300 mg twice daily) for the treatment of allergic rhinitis achieved positive results. All treated patients (n=69) reported improved global assessments, with 58 percent noting symptom abatement and 48 percent recording equivalent or increased response with *Urtica dioica* compared to previous medicine.⁸⁸

The mechanism of nettle as an anti-inflammatory is unclear; however, the answer may lie in nettle's histamine content. Histamine down-regulates the function of human polymorphonuclear leukocytes (PMNs)⁸⁹ and reduces biosynthesis of leukotriene B4 (LTB4) by inhibiting at least three of its induction pathways. LTB4 increases edema and chemotaxis, induces release of lysosomal enzymes, increases reactive oxygen species, and enhances production of the cytokines TNF- α , IL-1, and IL-6.

Urtica dioica may be seen as a therapeutic adjunct in sinusitis or as a pivotal therapy in patients with a predominantly allergic CRS etiology. An adult dose of 300 mg twice daily of freeze-dried *Urtica* is recommended.

Alternative Procedures

Nasal Irrigation

Irrigation of the nasal mucosa with a hypertonic solution facilitates the removal of mucoid secretions and cleanses associated nasal tissues (Figure 4). Irrigation with a 5-percent saline solution produces significantly better mucociliary clearance, compared to both 3- and 0.9-percent solutions,^{90,91} and results in significant reductions in nasal histamine concentrations for up to six hours after administration. One study also revealed significant reductions in leukotriene C4 (LTC4) concentration for up to four hours.⁹² (LTC4 promotes edema and is metabolized into LTD4, and then LTE4, which is considered similar to histamine in action, albeit stronger.)

Numerous studies support adjunctive use of nasal irrigation in sinusitis. Although nasal air flow was not significantly improved with saline irrigation in chronic sinusitis, improvements in subjective complaints, endonasal endoscopy, and radiography were noted.⁹³ In 2002, Rabago et al observed significant changes in Rhinosinusitis Disability Index (RSDI) and the sinus-symptom severity assessment (SIA) with concurrent significant improvement in quality of life assessment;⁹⁴ these results were duplicated in a 2005 study.⁹⁵ Overall, side effects were minor, perhaps explaining an 87-percent compliance rate for this simple intervention.⁹⁴

The addition of baking soda to saline irrigation has been effectively employed by naturopathic physicians and appears to inhibit the activity of histamine through increasing the alkalinity of sinus tissue.⁹⁶ Powdered extracts of *Berberis aquifolium*, *Berberis vulgaris*, *Hydrastis canadensis*, and other berberine-containing botanicals can also be added to irrigation protocols. The alkaloid berberine exerts antibacterial, antifungal,⁹⁷⁻¹⁰⁰ and anti-inflammatory effects.¹⁰¹

Nasal irrigation is a simple, inexpensive treatment that is well tolerated, effective, and could help minimize antibiotic use and subsequent microbial resistance. Irrigation with a 5-percent saline solution 1-3 times daily has been suggested to relieve a variety of sinus and nasal symptoms. Saline irrigation has also been safely used in pediatrics (three times daily) for up to seven weeks in two allergic rhinitis studies, with significant reduction in antihistamine intake and daily rhinitis score.^{102,103}

Naso-Sympatico Treatment

An osteopathic technique involves direct massage of the sinus ostea with surgical cotton swabs.¹⁰⁴ Application of diluted botanical essential oils (naso-sympatico treatment) into the sinus ostea via a cotton swab appears to act as a localized decongestant as well as inducing sympathetic tone to the sphenopalatine ganglion¹⁰⁵ – the regulator of secretomotor function for mucus membranes of sinuses, the nose, and the eustachian tubes. The volatile nature of essential oils induces a rapid effect, with lacrimation, loosening of mucus, and enhanced drainage of the nose and sinuses.

In chronic sinusitis, Mark Lamden, ND, retains the swabs at the ostea for 20-30 minutes and reports 50-percent efficacy when using naso-sympatico in conjunction with allergy treatment.¹⁰⁶ The most common essential oils used include eucalyptus, lavender, pine, thyme, and clove. Camphor oil inhalation has traditionally been used to help liquefy the tenacious mucus of sinusitis,¹⁰⁷ although its employment in naso-sympatico treatment is undocumented. These and other essential oils are also antifungal in nature,¹⁰⁸ which may provide another mechanism for their benefit in CRS.

Lifestyle Considerations

Air Quality

Modern indoor living is often a perpetuating influence in sinusitis. Household mold levels often outstrip ubiquitous outdoor airborne fungi levels, although use of high quality particulate air (HEPA) filtration reduces indoor levels¹⁰⁹ and sinusitis risk.¹¹⁰ Decreased exposure to animal dander and dust mites, including removal of carpeting and feather bedding, often improves recurrent sinusitis.^{110,111} One study found a dose-response relationship between natural gas used for home cooking and children with respiratory disease (including sinusitis), but interestingly, passive cigarette smoke revealed no significant connection to childhood infirmity.¹¹²

Coughing, sneezing, and blowing the nose help remove particulate-dense mucus from the body. Unfortunately, CT analysis reveals that the tradition of blowing mucus out the nasal passages generates enough pressure to propel 1 mL of fluid into the maxillary sinus from a single nose blow; sneezing and coughing do not generate similar pressure.¹¹³ The pain reduction often noted after nose blowing (the result of air rushing into the sinus cavity restoring atmospheric pressure) is only temporarily palliative and may perpetuate chronicity.

Dietary Factors

Clinically, the treatment of sinusitis appears to require a holistic approach that often requires dietary change. In fact, many naturopathic physicians suggest food allergy or sensitivities are often obstacles to curing sinusitis. Peter D'Adamo, ND, in his popular blood-type diet books, suggests food lectins are the molecular perpetuator of sinus inflammation.¹¹⁴ It has also been suggested that dairy, wheat, and corn promote a more globular than planar mucus, disable sinus drainage, and promote antigen exposure.⁹ In addition, lactose intolerance has been noted to cause systemic symptoms, including CRS, in certain individuals.¹¹⁵

In the predisposed, introduction of specific foods may decrease immune system tolerance and perpetuate sinusitis as resources are diverted to compensate for the inflammatory stimulus. The idea that there are mucus-promoting foods, however, may be

an oversimplified generalization.¹¹⁶ More appropriate may be an understanding that specific foods may exacerbate allergies/sensitivities in the subset of individuals whose immunological burden is currently elevated.

Conclusion

Chronic rhinosinusitis is a condition of entrained dysregulation in which the sinus mucosa cannot successfully regulate mucus production or reduce inflammation to restore sinus drainage. Newer evidence points to an allergic etiology in the majority of CRS cases, in which the immune system hyperreacts to ubiquitous fungi in the nose and sinuses. This necessitates not only removal of thick, eosinophil-laden mucus via nasal lavage, naso-sympatico, or endoscopic surgery, but the underlying immune/inflammatory dysregulation as well. It should also be of benefit to eradicate inciting microorganisms, whether bacterial or fungal. It appears the best treatment is a multi-modal approach that includes treatments listed in the body of this article, as well as reduction of fungi and bacteria in the home environment, and attention to foods or other lifestyle choices that appear to exacerbate the condition.

References

1. Van Cauwenberge P, Watelet JB. Epidemiology of chronic rhinosinusitis. *Thorax* 2000;55:S20-21.
2. Bhattacharyya N. The economic burden and symptom manifestations of chronic rhinosinusitis. *Am J Rhinol* 2003;17:27-32.
3. Rubin MA, Gonzales R, Sande MA. Infections of the upper respiratory tract. In: Kasper DL, Braunwald E, Fauci AS, et al, eds. *Harrison's Principles of Internal Medicine*. 16th ed. New York, NY: McGraw-Hill; 2005:185-201.
4. Hallett R, Naguwa SM. Severe rhinosinusitis. *Clin Rev Allergy Immunol* 2003;25:177-190.
5. Prenner BM, Schenkel E. Allergic rhinitis: treatment based on patient profiles. *Am J Med* 2006;119:230-237.
6. Gwaltney JM Jr, Phillips CD, Miller RD, Riker DK. Computed tomographic study of the common cold. *N Engl J Med* 1994;330:25-30.
7. Lorenzi G, Bohm GM, Guimaraes ET, et al. Correlation between rheologic properties and *in vitro* ciliary transport of rat nasal mucus. *Biorheology* 1992;29:433-440.
8. King M, Agarwal M, Shukla JB. A planar model for mucociliary transport: effect of mucus viscoelasticity. *Biorheology* 1993;30:49-61.
9. Proefrock K. Botanical prescriptions for conditions of the eye including cataracts, glaucoma, allergy, and conjunctivitis. In: *Proceedings of the Southwest Conference on Botanical Medicine*. Tempe, AZ: Southwest College of Naturopathic Medicine Press; 2001:70.
10. Girod S, Zahm JM, Plotkowski C, et al. Role of the physicochemical properties of mucus in the protection of the respiratory epithelium. *Eur Respir J* 1992;5:477-487.
11. Atsuta S, Majima Y. Nasal mucociliary clearance of chronic sinusitis in relation to rheological properties of nasal mucus. *Ann Otol Rhinol Laryngol* 1998;107:47-51.
12. Engquist S, Lundberg C. Bacteria and inflammatory cells in maxillary sinusitis. *Arch Otorhinolaryngol* 1984;239:173-180.
13. Unal M, Tamer L, Pata YS, et al. Serum levels of antioxidant vitamins, copper, zinc and magnesium in children with chronic rhinosinusitis. *J Trace Elem Med Biol* 2004;18:189-192.
14. Nonoyama T, Harada T, Shinogi J, et al. Immunohistochemical localization of cytokines and cell adhesion molecules in maxillary sinus mucosa in chronic sinusitis. *Auris Nasus Larynx* 2000;27:51-58.
15. Ponikau JU, Sherris DA, Kern EB, et al. The diagnosis and incidence of allergic fungal sinusitis. *Mayo Clin Proc* 1999;74:877-884.
16. Collins M, Nair S, Smith W, et al. Role of local immunoglobulin E production in the pathophysiology of noninvasive fungal sinusitis. *Laryngoscope* 2004;114:1242-1246.
17. Shin SH, Ponikau JU, Sherris DA, et al. Chronic rhinosinusitis: an enhanced immune response to ubiquitous airborne fungi. *J Allergy Clin Immunol* 2004;114:1369-1375.
18. Manning SC, Mabry RL, Schaefer SD, Close LG. Evidence of IgE-mediated hypersensitivity in allergic fungal sinusitis. *Laryngoscope* 1993;103:717-721.
19. Schubert MS. Allergic fungal sinusitis. *Otolaryngol Clin North Am* 2004;37:301-326.
20. Campbell JM, Graham M, Gray HC, et al. Allergic fungal sinusitis in children. *Ann Allergy Asthma Immunol* 2006;96:286-290.
21. Ponikau JU, Sherris DA, Kephart GM, et al. The role of ubiquitous airborne fungi in chronic rhinosinusitis. *Curr Allergy Asthma Rep* 2005;5:472-476.

22. Sasama J, Sherris DA, Shin SH, et al. New paradigm for the roles of fungi and eosinophils in chronic rhinosinusitis. *Curr Opin Otolaryngol Head Neck Surg* 2005;13:2-8.
23. Braun H, Stammberger H, Buzina W, et al. Incidence and detection of fungi and eosinophilic granulocytes in chronic rhinosinusitis. *Laryngorhinootologie* 2003;82:330-340. [Article in German]
24. Tosca MA, Cosentino C, Pallestrini E, et al. Improvement of clinical and immunopathologic parameters in asthmatic children treated for concomitant chronic rhinosinusitis. *Ann Allergy Asthma Immunol* 2003;91:71-78.
25. Oliveira CA, Sole D, Naspitz CK, Rachelefsky GS. Improvement of bronchial hyperresponsiveness in asthmatic children treated for concomitant sinusitis. *Ann Allergy Asthma Immunol* 1997;79:70-74.
26. Scheid DC, Hamm RM. Acute bacterial rhinosinusitis in adults: part I. Evaluation. *Am Fam Physician* 2004;70:1685-1692.
27. Evans FO Jr, Sydnor JB, Moore WE, et al. Sinusitis of the maxillary antrum. *N Engl J Med* 1975;293:735-739.
28. Makela MJ, Puhakka T, Ruuskanen O, et al. Viruses and bacteria in the etiology of the common cold. *J Clin Microbiol* 1998;36:539-542.
29. Yuta A, Doyle WJ, Gaumond E, et al. Rhinovirus infection induces mucus hypersecretion. *Am J Physiol* 1998;274:L1017-L1023.
30. Ebenfelt A. Bacterial location in chronic sinusitis. *Am J Rhinol* 2005;19:458-461.
31. Williams JW Jr, Aguilar C, Cornell J, et al. Antibiotics for acute maxillary sinusitis. *Cochrane Database Syst Rev* 2006;3:CD000243.
32. deShazo RD, Chapin K, Swain RE. Fungal sinusitis. *N Engl J Med* 1997;337:254-259.
33. deShazo RD, O'Brien M, Chapin K, et al. Criteria for the diagnosis of sinus mycetoma. *J Allergy Clin Immunol* 1997;99:475-485.
34. Shin SH, Heo WW. Effects of unilateral naris closure on the nasal and maxillary sinus mucosa in rabbit. *Auris Nasus Larynx* 2005;32:139-143.
35. Drettner B, Johansson P, Kumlien J. Experimentally induced sinusitis: the importance of vasomotor regulation. *Arch Otorhinolaryngol* 1989;246:315-317.
36. Aust R, Stierna P, Drettner B. Basic experimental studies of ostial patency and local metabolic environment of the maxillary sinus. *Acta Otolaryngol Suppl* 1994;515:7-10, discussion 11.
37. Johansson P, Kumlien J, Soderlund K, Hultman E. Experimental acute sinusitis in rabbits. Energy metabolism in sinus mucosa and secretion. *Acta Otolaryngol* 1988;106:460-467.
38. Miyaguchi M, Uda H, Sakai S. Na/K-ATPase in rabbit paranasal sinus mucosa during induced sinusitis. *Eur Arch Otorhinolaryngol* 1990;248:119-122.
39. Ali MS, Hutton DA, Wilson JA, Pearson JP. Major secretory mucin expression in chronic sinusitis. *Otolaryngol Head Neck Surg* 2005;133:423-428.
40. Kim DH, Chu HS, Lee JY, et al. Up-regulation of MUC5AC and MUC5B mucin genes in chronic rhinosinusitis. *Arch Otolaryngol Head Neck Surg* 2004;130:747-752.
41. Haruna S, Otori N, Moriyama H, Nakanishi M. Olfactory dysfunction in sinusitis with infiltration of numerous activated eosinophils. *Auris Nasus Larynx* 2006;33:23-30.
42. Ponikau JU, Sherris DA, Kephart GM, et al. Striking deposition of toxic eosinophil major basic protein in mucus: implications for chronic rhinosinusitis. *J Allergy Clin Immunol* 2005;116:362-369.
43. Westrin KM, Stierna P, Soderlund K, Carlsoo B. Lactic acid isomers and fatty acids in sinus secretion: a longitudinal study of bacterial and leukocyte metabolism in experimental sinusitis. *Scand J Infect Dis* 1992;24:765-772.
44. Pawankar R. Mast cells in allergic airway disease and chronic rhinosinusitis. *Chem Immunol Allergy* 2005;87:111-129.
45. Eggesbo HB. Radiological imaging of inflammatory lesions in the nasal cavity and paranasal sinuses. *Eur Radiol* 2006;16:872-888.
46. Bhattacharyya N. The completely opacified frontal or sphenoid sinus: a marker of more severe disease in chronic rhinosinusitis? *Laryngoscope* 2005;115:2123-2126.
47. Brandt ME, Warnock DW. Epidemiology, clinical manifestations, and therapy of infections caused by dematiaceous fungi. *J Chemother* 2003;15:36-47.
48. Ponikau JU, Sherris DA, Weaver A, Kita H. Treatment of chronic rhinosinusitis with intranasal amphotericin B: a randomized, placebo-controlled, double-blind pilot trial. *J Allergy Clin Immunol* 2005;115:125-131.
49. Weschta M, Rimek D, Formanek M, et al. Topical antifungal treatment of chronic rhinosinusitis with nasal polyps: a randomized, double-blind clinical trial. *J Allergy Clin Immunol* 2004;113:1122-1128.
50. Kennedy DW, Kuhn FA, Hamilos DL, et al. Treatment of chronic rhinosinusitis with high-dose oral terbinafine: a double blind, placebo-controlled study. *Laryngoscope* 2005;115:1793-1799.
51. Folker RJ, Marple BF, Mabry RL, Mabry CS. Treatment of allergic fungal sinusitis: a comparison trial of postoperative immunotherapy with specific fungal antigens. *Laryngoscope* 1998;108:1623-1627.

52. Benoliel P. Treatment of sino-nasal polyposis by *Candida albicans* immunotherapy: apropos of 4 cases. *Allerg Immunol (Paris)* 2001;33:388-394. [Article in French]
53. Hatipoglu U, Rubinstein I. Treatment of chronic rhinosinusitis with low-dose, long-term macrolide antibiotics: an evolving paradigm. *Curr Allergy Asthma Rep* 2005;5:491-494.
54. Wallwork B, Coman W. Chronic rhinosinusitis and eosinophils: do macrolides have an effect? *Curr Opin Otolaryngol Head Neck Surg* 2004;12:14-17.
55. Cervin A, Wallwork B. Anti-inflammatory effects of macrolide antibiotics in the treatment of chronic rhinosinusitis. *Otolaryngol Clin North Am* 2005;38:1339-1350.
56. Hemila H. Vitamin C intake and susceptibility to the common cold. *Br J Nutr* 1997;77:59-72.
57. Murray MT. A comprehensive review of vitamin C. *Am J Nat Med* 1996;3:8-21.
58. Clemetson CA. Histamine and ascorbic acid in human blood. *J Nutr* 1980;110:662-668.
59. Podoshin L, Gertner R, Fradis M. Treatment of perennial allergic rhinitis with ascorbic acid solution. *Ear Nose Throat J* 1991;70:54-55.
60. Braun JM, Schneider B, Beuth HJ. Therapeutic use, efficiency and safety of the proteolytic pineapple enzyme Bromelain-POS in children with acute sinusitis in Germany. *In Vivo* 2005;19:417-421.
61. Seltzer AP. Adjunctive use of bromelains in sinusitis: a controlled study. *Eye Ear Nose Throat Mon* 1967;46:1281-1288.
62. Taub SJ. The use of bromelains in sinusitis: a double-blind clinical evaluation. *Eye Ear Nose Throat Mon* 1967;46:361-362.
63. Rimoldi R, Ginesu F, Giura R. The use of bromelain in pneumological therapy. *Drugs Exp Clin Res* 1978;4:55-66.
64. Ako H, Cheung AH, Matsuura PK. Isolation of a fibrinolysis enzyme activator from commercial bromelain. *Arch Int Pharmacodyn Ther* 1981;254:157-167.
65. Taussig SJ. The mechanism of the physiological action of bromelain. *Med Hypotheses* 1980;6:99-104.
66. Felton GE. Does kinin released by pineapple stem bromelain stimulate production of prostaglandin E1-like compounds? *Hawaii Med J* 1977;36:39-47.
67. Kelly GS. Bromelain: a literature review and discussion of its therapeutic applications. *Altern Med Rev* 1996;1:243-257.
68. Sheffner AL. The reduction *in vitro* in viscosity of mucoprotein solution by a new mucolytic agent, N-acetyl-L-cysteine. *Ann N Y Acad Sci* 1963;106:298-310.
69. Todisco T, Polidori R, Rossi F, et al. Effect of N-acetylcysteine in subjects with slow pulmonary mucociliary clearance. *Eur J Respir Dis Suppl* 1985;139:136-141.
70. Stafanger G, Bisgaard H, Pedersen M, et al. Effect of N-acetylcysteine on the human nasal ciliary activity *in vitro*. *Eur J Respir Dis* 1987;70:157-162.
71. Hayashi H. Inhibitory effect of nasal mucus on the absorption of drugs through respiratory epithelium. *Nippon Jibiinkoka Gakkai Kaiho* 1990;93:40-49. [Article in Japanese]
72. De Vries N, De Flora S. N-Acetyl-L-Cysteine. *J Cell Biochem Suppl* 1993;17F:270-277.
73. De Flora S, Bennicelli C, Camoirano A, et al. *In vivo* effects of N-acetylcysteine on glutathione metabolism and on the biotransformation of carcinogenic and/or mutagenic compounds. *Carcinogenesis* 1985;6:1735-1745.
74. Della Loggia R, Ragazzi E, Tubaro A, et al. Anti-inflammatory activity of benzopyrones that are inhibitors of cyclo- and lipo-oxygenase. *Pharmacol Res Commun* 1988;20:91-94.
75. Kim HP, Mani I, Iversen L, Ziboh VA. Effects of naturally-occurring flavonoids and biflavonoids on epidermal cyclooxygenase and lipoxygenase from guinea pigs. *Prostaglandins Leukot Essent Fatty Acids* 1998;58:17-24.
76. Saija A, Scalese M, Lanza M, et al. Flavonoids as antioxidant agents: importance of their interaction with biomembranes. *Free Radic Biol Med* 1995;19:481-486.
77. Miller AL. Antioxidant flavonoids: structure, function and clinical usage. *Altern Med Rev* 1996;1:103-111.
78. Fox CC, Wolf EJ, Kagey-Sobotka A, Lichtenstein LM. Comparison of human lung and intestinal mast cells. *J Allergy Clin Immunol* 1988;81:89-94.
79. Bronner C, Landry Y. Kinetics of the inhibitory effect of flavonoids on histamine secretion from mast cells. *Agents Actions* 1985;16:147-151.
80. Otsuka H, Inaba M, Fujikura T, Kunitomo M. Histochemical and functional characteristics of metachromatic cells in the nasal epithelium in allergic rhinitis: studies of nasal scrapings and their dispersed cells. *J Allergy Clin Immunol* 1995;96:528-536.
81. Middleton E Jr, Drzewiecki G. Flavonoid inhibition of human basophil histamine release stimulated by various agents. *Biochem Pharmacol* 1984;33:3333-3338.
82. Shapiro AL, Rothman S. Undecylenic acid in the treatment of dermatomycoses. *Arch Derm Syphilol* 1945;52:166-171.
83. McLain N, Ascanio R, Baker C, et al. Undecylenic acid inhibits morphogenesis of *Candida albicans*. *Antimicrob Agents Chemother* 2000;44:2873-2875.
84. Neuhauser I. Successful treatment of intestinal moniliasis with fatty acid-resin complex. *AMA Arch Intern Med* 1954;93:53-60.
85. Oliver F, Amon EU, Breathnach A, et al. Contact urticaria due to the common stinging nettle (*Urtica dioica*) – histological, ultrastructural and pharmacological studies. *Clin Exp Dermatol* 1991;16:1-7.
86. Collier HO, Chester GB. Identification of 5-hydroxytryptamine in the sting of the nettle (*Urtica dioica*). *Br J Pharmacol Chemother* 1956;11:186-189.

87. Saxena PR, Pant MC, Kishor K, Bhargava KP. Identification of pharmacologically active substances in the Indian stinging nettle, *Urtica parviflora* (Roxb.). *Can J Physiol Pharmacol* 1965;40:869-876.
88. Mittman P. Randomized, double-blind study of freeze-dried *Urtica dioica* in the treatment of allergic rhinitis. *Planta Med* 1990;56:44-47.
89. Flamand N, Plante H, Picard S, et al. Histamine-induced inhibition of leukotriene biosynthesis in human neutrophils: involvement of the H2 receptor and cAMP. *Br J Pharmacol* 2004;141:552-561.
90. Homer JJ, Dowley AC, Condon L, et al. The effect of hypertonicity on nasal mucociliary clearance. *Clin Otolaryngol Allied Sci* 2000;25:558-560.
91. Wabnitz DA, Wormald PJ. A blinded, randomized, controlled study on the effect of buffered 0.9% and 3% sodium chloride intranasal sprays on ciliary beat frequency. *Laryngoscope* 2005;115:803-805.
92. Georgitis JW. Nasal hyperthermia and simple irrigation for perennial rhinitis. Changes in inflammatory mediators. *Chest* 1994;106:1487-1492.
93. Bachmann G, Hommel G, Michel O. Effect of irrigation of the nose with isotonic salt solution on adult patients with chronic paranasal sinus disease. *Eur Arch Otorhinolaryngol* 2000;257:537-541.
94. Rabago D, Zgierska A, Mundt M, et al. Efficacy of daily hypertonic saline nasal irrigation among patients with sinusitis: a randomized controlled trial. *J Fam Pract* 2002;51:1049-1055.
95. Rabago D, Pasic T, Zgierska A, et al. The efficacy of hypertonic saline nasal irrigation for chronic sinonasal symptoms. *Otolaryngol Head Neck Surg* 2005;133:3-8.
96. Proefrock K. Botanical interventions for hyperactive immune systems. In: *Proceedings of the Southwest Conference on Botanical Medicine*. Tempe, AZ: Southwest College of Naturopathic Medicine Press; 2000:58-64.
97. Sun D, Courtney HS, Beachey EH. Berberine sulfate blocks adherence of *Streptococcus pyogenes* to epithelial cells, fibronectin, and hexadecane. *Antimicrob Agents Chemother* 1988;32:1370-1374.
98. Rehman J, Dillow JM, Carter SM, et al. Increased production of antigen-specific immunoglobulins G and M following *in vivo* treatment with the medicinal plants *Echinacea angustifolia* and *Hydrastis canadensis*. *Immunol Lett* 1999;68:391-395.
99. Scazzocchio F, Cometa MF, Tomassini L, Palmery M. Antibacterial activity of *Hydrastis canadensis* extract and its major isolated alkaloids. *Planta Med* 2001;67:561-564.
100. Pasqual MS, Lauer CP, Moyna P, Henriques JA. Genotoxicity of the isoquinoline alkaloid berberine in prokaryotic and eukaryotic organisms. *Mutat Res* 1993;286:243-252.
101. Ckless K, Schlottfeldt JL, Pasqual M, et al. Inhibition of *in-vitro* lymphocyte transformation by the isoquinoline alkaloid berberine. *J Pharm Pharmacol* 1995;47:1029-1031.
102. Garavello W, Di Berardino F, Romagnoli M, et al. Nasal rinsing with hypertonic solution: an adjunctive treatment for pediatric seasonal allergic rhinoconjunctivitis. *Int Arch Allergy Immunol* 2005;137:310-314.
103. Garavello W, Romagnoli M, Sordo L, et al. Hypersaline nasal irrigation in children with symptomatic seasonal allergic rhinitis: a randomized study. *Pediatr Allergy Immunol* 2003;14:140-143.
104. Leim T. *Cranial Osteopathy: Principles and Practice*. New York, NY: Elsevier Churchill Livingstone; 2004:514-517.
105. Klinghardt D. The sphenopalatine ganglion (spg) and environmental sensitivity. International Symposium on Man and his Environment. American Environmental Health Foundation, Dallas, TX. June 9-12, 2005.
106. Personal communication, Mark Lamden, ND. May 24, 2006.
107. Kuts-Cheraux AW. *Naturae Medicina and Naturopathic Dispensatory*. Des Moines, IA: American Naturopathic Physicians and Surgeons Association; 1953:37,82.
108. Giordani R, Regli P, Kaloustian J, et al. Antifungal effect of various essential oils against *Candida albicans*. Potentiation of antifungal action of amphotericin B by essential oil from *Thymus vulgaris*. *Phytother Res* 2004;18:990-995.
109. Hardin BD, Kelman BJ, Saxon A. Adverse human health effects associated with molds in the indoor environment. *J Occup Environ Med* 2003;45:470-478.
110. Dennis DP. Chronic sinusitis: defective T-cells responding to superantigens, treated by reduction of fungi in the nose and air. *Arch Environ Health* 2003;58:433-441.
111. Evans R 3rd. Environmental control and immunotherapy for allergic disease. *J Allergy Clin Immunol* 1992;90:462-468.
112. Wong TW, Yu TS, Liu HJ, Wong AH. Household gas cooking: a risk factor for respiratory illnesses in preschool children. *Arch Dis Child* 2004;89:631-636.
113. Gwaltney JM Jr, Hendley JO, Phillips CD, et al. Nose blowing propels nasal fluid into the paranasal sinuses. *Clin Infect Dis* 2000;30:387-391.
114. D'Adamo P. *Eat Right for Your Type: Complete Blood Type Encyclopedia*. New York, NY: Riverhead Books; 2002:408-409.
115. Matthews SB, Waud JP, Roberts AG, Campbell AK. Systemic lactose intolerance: a new perspective on an old problem. *Postgrad Med J* 2005;81:167-173.
116. Wuthrich B, Schmid A, Walther B, Sieber R. Milk consumption does not lead to mucus production or occurrence of asthma. *J Am Coll Nutr* 2005;24:547S-555S.